

Psychosis in a Patient with Porencephaly – A Case Report

Tajamul Hussain¹, Jahangeer Ahmad Bhat², Sheikh Shoib¹, Mahak Shafat³, Raheel Mushtaq¹, Altaf Ahmad Malla¹

¹Senior Resident, Department of Psychiatry, Govt. Medical College, Srinagar, Jammu and Kashmir, India

²Senior Resident, Department of Radiodiagnosis, Govt. Medical College, Srinagar, Jammu and Kashmir, India

³Post Graduate Scholar, Department of Pathology, Sher-i-Kashmir Institute of Medical Sciences, Srinagar, Jammu and Kashmir, India

ABSTRACT

Porencephaly is a rare congenital disorder of the central nervous system involving a cyst or a cavity filled with cerebrospinal fluid in brain's parenchyma. Prefrontal cortical dysfunction is often associated with development of psychotic symptoms. We present a case of a 26-year-old female with first episode of psychosis who was found to

be suffering from porencephaly of left frontal cortex. There are only a few case reports of porencephaly associated with psychosis in literature. Porencephaly may contribute to the development of psychosis, especially if located in the frontal lobe of brain.

Keywords: Porencephaly; Central Nervous System; Cyst; Psychosis; Frontal lobe

INTRODUCTION

Porencephaly is an extremely rare disorder involving encephalomalacia. It is a neurological disorder of the central nervous system characterized with cysts or cavities within the cerebral hemisphere [1]. The term 'porencephaly' was coined by Heschl in 1859 to describe a cavity in the human brain [2]. It is caused by either local damage from ischemia in the brain hemisphere, or most commonly, hemorrhage after birth. It can also occur as a consequence of abnormal development before birth [3, 4]. The cysts and cavities cause a wide range of physiological, physical, and neurological symptoms [5]. Depending on the patient, this disorder may cause only minor neurological problems without any disruption in intelligence, while others may be severely disabled or die before the second decade of their lives. In rare cases, it may present with psychiatric manifestations like psychosis. Prefrontal cortex and limbic system hypotheses are the predominant neuroanatomical hypotheses of psychosis. Other causes in psychotic patients include decreased prefrontal grey or white matter volume or disturbed prefrontal metabolism and blood flow, as well as decreased hippocampal and entorhinal cortex volume. All these are strong indications that prefrontal cortical regions are associated with psychosis [6-8]. Thus, patients with porencephalic cysts especially in

frontal or temporal lobes can develop psychotic symptoms.

CASE REPORT

A 26-year-old female was brought to the psychiatric outpatient department by her husband with one week history of suspicious behavior, aggressive outbursts and hearing voices. Her husband reported that over the past one week she became extremely suspicious of the people around her including her husband and accused them of trying to conspire against her. She would become aggressive whenever her belief was challenged by family or friends. She also complained of hearing her neighbors talking bad things about her. She had no past psychiatric history or family history of a psychiatric disorder. The patient had no speech development problems or severe mental retardation that is often associated with porencephaly. Her medical history included three years of migraine headaches for which she took NSAIDs occasionally.

On mental state examination, she was oriented to time, place and person but was extremely guarded and did not talk much. She looked suspicious and was scanning the interview room. She verbalized her mood as 'low' but attributed it to the fact that people were against her. There was no formal thought disorder but she had predominant persecutory delusions. Although not

Conflict of Interest: None declared

This article has been peer reviewed.

Article Submitted on: 29th August 2014

Article Accepted on: 23rd October 2014

Funding Sources: None declared

Correspondence to: Dr Tajamul Hussain

Address: Department of Psychiatry, Government Medical College, Srinagar, Jammu and Kashmir, India

Email: dhartajamul@gmail.com

Cite this Article: Hussain T, Bhat JA, Shoib S, Shafat M, Mushtaq R, Malla AA. Psychosis in a patient with porencephaly - a case report. *J Pioneer Med Sci.* 2015; 5(1):26-28

actively hallucinating at the time of interview, she acknowledged hearing voices of people talking bad about her. She had no insight into the nature of her illness.

Physical examination was normal and no abnormality was detected on neurological examination. Mini mental examination score was also normal (30/30). A neuropsychological examination showed no alterations, with intelligent quotient in the normal range.

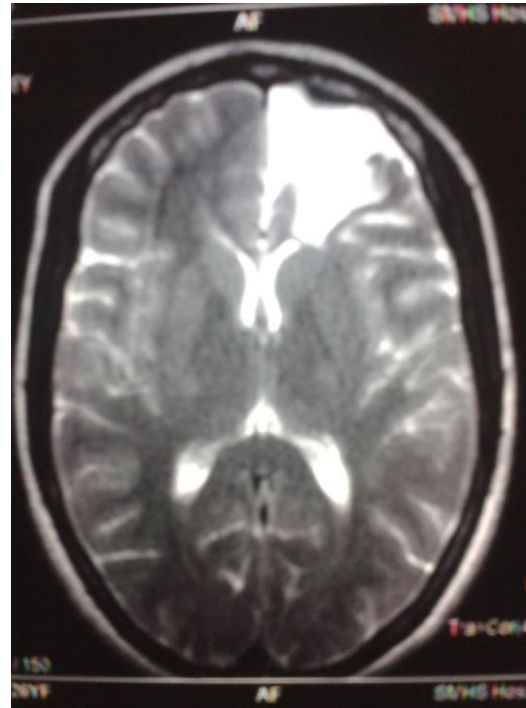
Hematological and biochemistry blood test results, thyroid tests, toxicological tests, gonadotropins and cortisol levels were within normal range and did not reveal any other related medical condition.

A brain MRI was performed which revealed the existence of a large porencephalic cyst on the left side of frontal lobe. In view of her psychotic symptoms, patient was started on oral olanzapine 10 mg per day. Over a period of two weeks, she showed marked improvement with no auditory hallucinations or aggressive outbursts. Although her delusions still persisted, she had gained some insight into the falseness of her beliefs.

Figure 1: Sagittal T1 weighted image shows hypointense porencephalic cyst in left side of frontal lobe

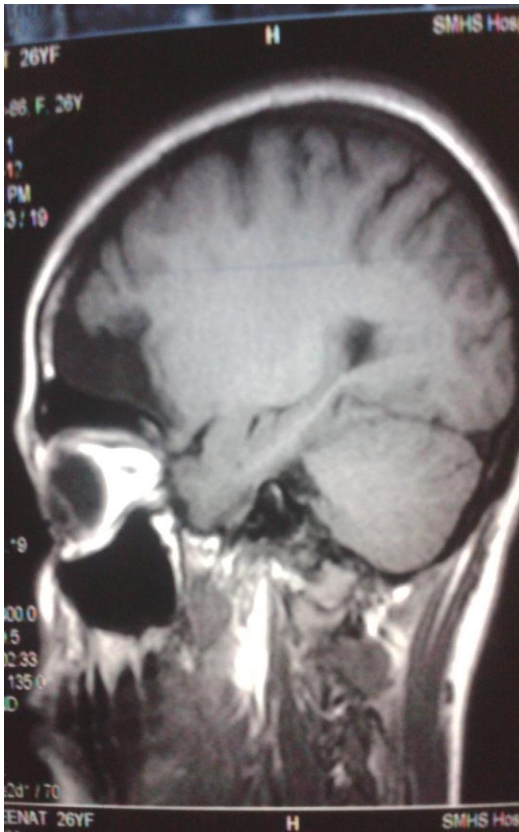

Figure 2: Axial T2 weighted image shows porencephalic cyst in left side of frontal lobe. The lesion shows CSF signal intensity.



DISCUSSION

This patient was diagnosed with porencephaly based on MRI findings, although she did not have other clinical features of porencephaly like mental retardation, seizures or spastic paralysis. The location of porencephalic cyst in frontal and temporal lobes can be associated with psychotic features, or one can suggest that damaged brain regions possibly triggered the patient's potential vulnerability to psychotic symptoms. There are a few case reports in literature linking porencephaly with psychosis. Pae et al in 2009 reported the case of a patient who developed a psychotic episode possibly associated with multiple leukoencephalomalacia and porencephalic changes in the brain cortex. In this case, a 30-year-old woman had persecutory ideas and visual hallucinations. Multiple focal leukoencephalomalacia changes in the left frontal lobe, bilateral occipital lobes and left basal ganglia, and a large porencephalic change in the right temporal lobe was found with MRI [9]. Schizencephaly is also a rare congenital neurodevelopmental disorder of brain cortex which is characterized by abnormal slits or clefts in the cerebral hemispheres. That malformation is a form of porencephaly. It appears with paresis,

mental retardation and seizures too [10]. Alexander et al reported two cases with schizencephaly associated with psychosis. The first patient had seizures, mental retardation and psychotic features like delusions and auditory hallucinations. The second patient had monoplegia, mental retardation and delusions [11]. Relan et al presented a case with unilateral schizencephaly cleft associated with bipolar disorder. This patient was overactive and over-social. She also had mild motor impairment, mental retardation and presented with persecutory ideation and auditory hallucinations [12]. Overall, there was only one case of porencephaly and psychosis and three cases of schizencephaly (which is considered to be a variation of porencephaly) and psychosis.

CONCLUSION

Frontal and especially temporal lobe structure and function are consistently implicated in radiological imaging literature (brain imaging research) in schizophrenia. The above case report and review of literature showed that there are only a few cases with porencephalic cysts and psychosis as well as three cases of schizencephaly. The damaged brain regions in these cases are associated with psychotic symptoms. The presence of neurodevelopment anomalies may have pathoplastic effect on the manifestation of psychosis. We hypothesize that this patient's brain lesions have a crucial influence on her vulnerability to psychotic symptoms. One can assume that even old lesions on the left frontal lobes can be an additional risk factor for the development of the disorder. She had no past or family psychiatric history and this was her first psychotic episode. Lesions in these areas have been associated with psychosis. This case highlights the need that in patients with similar clinical features as described above, radiological examination should be carried out so as to discover damaged brain lesions.

REFERENCES

1. Gul A, Gungorduk K, Yildirim G, Gedikbasi A, Ceylan Y. Prenatal diagnosis of porencephaly secondary to maternal carbon monoxide poisoning. *Arch Gynecol Obstet* 2009; 279:697-700.
2. Hirowatari C, Kodama R, Sasaki Y, Tanigawa Y, Fujishima J, Yoshikawa T, et al. Porencephaly in a Cynomolgus Monkey (*Macaca Fascicularis*). *J Toxicol Pathol* 2012; 25:45-49.
3. Ho SS, Kuzniesky RI, Gilliam F, Faught E, Bebin M, Morawetz R. Congenital porencephaly: MR features and relationship to hippocampal sclerosis. *AJNR Am J*

4. *Neuroradiol* 1998; 19:135-141.
4. Stevenson RE, Hall JG. Porencephaly. *Human Malformations and related Anomalies* Oxford University Press, 2006, 645-654.
5. Yoneda Y, Haginoya K, Arai H, Yamaoka S, Tsurusaki Y, Doi H, et al. De novo and inherited mutations in COL4A2, encoding the type IV collagen $\alpha 2$ chain cause porencephaly. *Am J Hum Genet* 2012; 90:86-90.
6. Buchanan RW, Carpenter WT. Schizophrenia and Other Psychotic Disorders. *Kaplan & Sadock's Comprehensive Textbook of Psychiatry* Lippincott Williams & Wilkins, 2005, 1329-1371.
7. Saugstad LF. What is psychosis and where is it located? *Eur Arch Psychiatry Clin Neurosci* 2008; 258 Suppl 2:111-117.
8. Wood SJ, Pantelis C, Velakoulis D, Yucel M, Fornito A, McGorry PD. Progressive changes in the development toward schizophrenia: studies in subjects at increased symptomatic risk. *Schizophr Bull* 2008; 34:322-329.
9. Pae CU, Kim JH. The leukoencephalomalacia and porencephalia changes in the brain and the potential usefulness of olanzapine treatment. *CNS Spectr* 2009; 13:e1.
10. Packard AM, Miller VS, Delgado MR. Schizencephaly: correlations of clinical and radiological features. *Neurology* 1997; 48:1427-1434.
11. Alexander RC, Patkar AA, Lapointe JS, Flynn SW, Honer WG. Schizencephaly associated with psychosis. *J Neurol Neurosurg Psychiatry* 1997; 63:373-375.
12. Relan P, Chatuverdi SK, Shetty B. Schizencephaly associated with bipolar affective disorder. *Neurol India* 2002; 50:194-197.