

# Propylthiouracil Induced Vasculitis: A Rare Adverse Event

N.S. Neki<sup>1</sup>

<sup>1</sup>Professor of Medicine, Government Medical College and Guru Nanak Dev Hospital, Amritsar, India

## ABSTRACT

Antithyroid drug therapy with propylthiouracil (PTU) is commonly used in patients with Grave's disease. Common side effects of PTU include leukopenia, agranulocytosis, skin rash and abnormal liver function tests. Rarely, it can induce anti-neutrophil cytoplasmic antibody

(ANCA) associated vasculitis which is a serious adverse effect during PTU therapy for Grave's disease. Withdrawal of PTU and the administration of corticosteroids ameliorates these manifestations. A case of propylthiouracil induced vasculitis is being reported here.

Keywords: Propylthiouracil; Vasculitis; ANCA; Grave's disease.

## INTRODUCTION

Propylthiouracil (PTU) is a commonly used antithyroid drug for Grave's disease. It is known to cause many adverse effects such as granulocytopenia, urticaria, pruritis, fever, hepatotoxicity, myalgia and arthralgia. One of the most serious complications of PTU is the development of vasculitis [1, 2]. A case of perinuclear anti-neutrophil cytoplasmic antibodies (p-ANCA) positive vasculitis during PTU therapy for Grave's disease is being reported here for its rarity from this part of the country, which improved significantly with stopping of PTU and administration of corticosteroids. The prime rationale of reporting this case scenario is to familiarize the healthcare professionals with biological behavior, clinical characteristics, diagnostic work-up and therapeutic strategies of this rare entity.

## CASE REPORT

A 38-year-old female with known Grave's disease presented in the emergency with complaints of palpitations, sweating, heat intolerance and skin lesions on the legs. She was taking propylthiouracil 300 mg twice daily since 18 months. She had no history of thromboembolic disease, deep vein thrombosis, pulmonary embolism, coagulopathies, miscarriages or drug abuse. She was clinically hyperthyroid. On physical examination, she had diffuse goiter with bilateral exophthalmos, fever and tachycardia (120 BPM). Examination of right

leg revealed tender hemorrhagic bullae with erythematous base (Figure 1). Laboratory profile revealed hemoglobin 11.3 g/dl, total leucocyte count 10800/mm<sup>3</sup>, platelet count 120000/mm<sup>3</sup>, erythrocyte sedimentation rate 55mm/hour, C-reactive protein increased, T3 1.29 ng/ml (normal 0.8-2.0 ng/ml), free T4 14.2 pmol/L (normal 12-22 pmol/L), thyroid stimulating hormone 1.29 mIU/L (normal 0.27-4.25 mIU/L), blood urea 20 mg/dL and serum creatinine 1.2 mg/dL. Thyroid peroxidase antibodies 572 IU/ml (normal 0-50 IU/ml), p-ANCA strongly positive (1:320), c-ANCA negative, antimyeloperoxidase (anti-MPO) antibodies 42.3 RU/ml (normal 0-20 RU/ml), anticardiolipin IgM antibody positive 115 MPL U/ml (normal <10 MPL U/ml), rheumatoid factor negative, lupus erythematosus (LE) cell negative, antinuclear antibodies negative, anti-double stranded DNA antibodies negative. Prothrombin time, activated partial thromboplastin time and urine analysis were within normal limits. Electrocardiogram, 2D echocardiography and chest X-ray were normal. Thyroid scan revealed increased thyroid uptake (8.9%). Skin biopsy showed leukocytoclastic vasculitis characterized by endothelial swelling, marked perivascular infiltration of neutrophils with evidence of leukocytic nuclei around the vessels (Figure 2). In view of the history, skin lesions and strongly positive p-ANCA, a diagnosis of PTU induced vasculitis was made. The PTU was immediately discontinued and the patient was started on prednisolone 30mg/day for 2 weeks. The titer of anti-MPO antibodies and p-ANCA decreased and skin lesions improved. The

Conflict of Interest: None declared

This article has been peer reviewed.

Article Submitted on: 1<sup>st</sup> January 2015

Article Accepted on: 10<sup>th</sup> May 2015

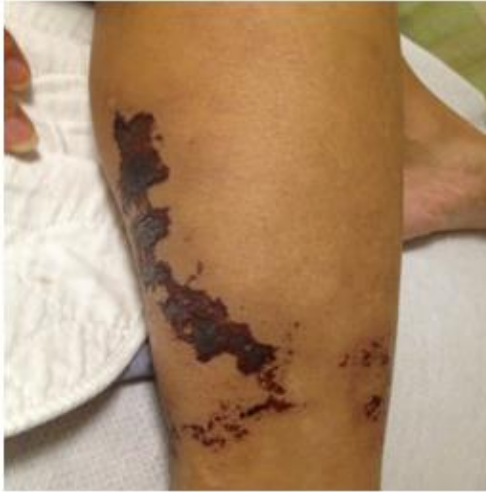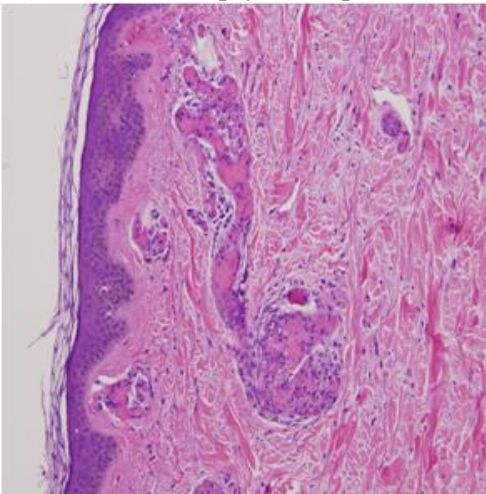
Funding Sources: None declared

Correspondence to: Dr N.S. Neki

Address: Department of Medicine, Government Medical College and Guru Nanak Dev Hospital, Amritsar, India

Email: [drneki123@gmail.com](mailto:drneki123@gmail.com)

Cite this Article: Neki NS. Propylthiouracil induced vasculitis: a rare adverse event. *J Pioneer Med Sci*. 2015; 5(4):130-132

**Figure 1:** Right leg of the patient**Figure 2:** Skin biopsy of the patient

patient was started on radioactive iodine for Grave's disease as she did not agree for thyroidectomy. During the 6 months follow-up, she had no recurrence of skin lesions and was leading a normal life.

## DISCUSSION

Vasculitis is the rarest manifestation of PTU therapy. In most cases, the symptoms develop many months after start of therapy [3]. The proportion of patients positive for anti-MPO (p-ANCA) increases with prolonged of PTU therapy as reported by Sera et al [4]. Leukocytoclastic vasculitis has been found most commonly with PTU therapy and not with methimazole [5]. Clinical findings such as urticaria, pruritis, maculopapular and papular-purpuric rashes, arthralgia, myalgia, fever, agranulocytosis, aplastic anemia, thrombocytopenia, hepatitis,

pericarditis, nephritis, alveolar haemorrhage, polyarteritis nodosa, vasculitis and disseminated intravascular coagulation have been reported in PTU induced vasculitis [2]. In some cases, the clinical features of vasculitis may be entirely confined to breasts, ears and extremities [6]. Our patient had skin lesions on the right leg, suggestive of vasculitis, which regressed when PTU was discontinued and prednisolone was started. The laboratory findings of positive p-ANCA and negative c-ANCA strongly suggested PTU induced vasculitis. The pathogenesis of PTU induced vasculitis is not completely understood. Khanolkar et al in their study revealed that PTU accumulates within neutrophils, bind to MPO to alter its configuration ultimately resulting in antibody formation by polyclonal activation of B lymphocytes in susceptible persons [7]. Biopsy of skin lesions is characterized by endothelial swelling, extravasation of erythrocytes and marked perivascular neutrophils infiltration with evidence of fragmented leukocytic nuclei in and around the vessels thus suggestive of leukocytoclastic vasculitis [8]. The findings of skin biopsy of our patient were suggestive of leukocytoclastic vasculitis. PTU associated vasculitis carries less morbidity, mortality and recurrence compared to primary vasculitis. The patient should be put on immunosuppressive therapy (corticosteroid) for a shorter period unlike that of primary vasculitis [9].

## REFERENCES

1. Ashizawa K, Eguchi K. Serum anti-myeloperoxidase antineutrophil cytoplasmic antibodies (MPO-ANCA) in patients with Graves' disease receiving anti-thyroid medication. *Intern Med* 2003; 42:463-464.
2. Azizi F. The safety and efficacy of antithyroid drugs. *Expert Opin Drug Saf* 2006; 5:107-116.
3. Khursid I, Sher J. Disseminated intravascular coagulation and vasculitis during propylthiouracil therapy. *Postgrad Med J* 2000; 76:185-186.
4. Sera N, Ashizawa K, Ando T, Abe Y, Ide A, Usa T, et al. Treatment with propylthiouracil is associated with appearance of antineutrophil cytoplasmic antibodies in some patients with Graves' disease. *Thyroid* 2000; 10:595-599.
5. Harper L, Chin L, Daykin J, Allahabadia A, Heward J, Gough SC, et al. Propylthiouracil and carbimazole associated-antineutrophil cytoplasmic antibodies (ANCA) in patients with Graves' disease. *Clin Endocrinol (Oxf)* 2004; 60:671-675.
6. Mathieu E, Fain O, Sitbon M, Thomas M. Systemic adverse effect of antithyroid drugs. *Clin Rheumatol* 1999; 18:66-68.
7. Khanolkar MP, Owen PJD, Lazarus JH. Propylthiouracil induced ANCA positive vasculitis: a Case Report. *Int J Endocrinol Metab* 2004; 2:47-50.
8. Vasily DB, Tyler WB. Propylthiouracil-induced

- cutaneous vasculitis. Case presentation and review of the literature. *JAMA* 1980; 243:458-461.
9. Gao Y, Chen M, Ye H, Yu F, Guo XH, Zhao MH. Long-term outcomes of patients with propylthiouracil-induced anti-neutrophil cytoplasmic auto-antibody-associated vasculitis. *Rheumatology (Oxford)* 2008; 47:1515-1520.