

Iatrogenic Brachiobasilic Fistula in a Hemodialysis Dependent Patient

Abdul Rehman Arshad¹, Farrukh Islam², Mohsin Qayyum³

¹Department of Nephrology, Combined Military Hospital, Peshawar, Pakistan

²Department of Nephrology, Combined Military Hospital Malir, Karachi, Pakistan

³Renal Medicine, Queen Elizabeth Hospital, Birmingham, United Kingdom

Vascular access is an essential requirement for hemodialysis and can be obtained temporarily through tunneled or non-tunneled dialysis catheters placed in the internal jugular, common femoral veins, or the subclavian veins. These catheters are often associated with complications such as the increased risk of infections, thrombotic occlusion, or central venous stenosis [1]. Surgically fashioned arteriovenous fistulas are the best long-term option, followed by arteriovenous grafts [2].

A 55-year-old male with End-Stage Renal Disease due to chronic glomerulonephritis presented to the nephrology clinic at the Military Hospital Rawalpindi for evaluation of poorly functioning fistula in the left arm. Before this, he had been receiving hemodialysis elsewhere. Physical examination showed a non-functional left arm brachiocephalic fistula, with scars of AV fistula surgery and needle marks suggesting

recent use. Examination of the right arm revealed thrill and bruit over the anterior aspect of the right upper arm, with only needle prick marks and no evidence of traumatic or surgical intervention (Figure 1).

Doppler scan of the right arm demonstrated a fistulous communication between the right brachial artery and basilic vein at the cubital fossa (Figure 2). The fistula was 2.8 mm in size, with a flow of 88 ml/min. The depth of the draining vein was 4 mm from the skin, with an internal diameter of 6 mm at the level of the fistula origin. We placed a temporary double lumen catheter in the right internal jugular vein for hemodialysis and consulted a vascular surgeon for permanent vascular access. An arteriovenous fistula had developed as a complication of inappropriate repeated needling of peripheral blood vessels.

Conflict of Interest:
None declared

This article has been peer reviewed.

Article Accepted on:
10th October 2020

Funding Sources:
None declared

Correspondence to:
Abdul Rehman Arshad

Address: Department of Nephrology, Combined Military Hospital, Peshawar, Pakistan

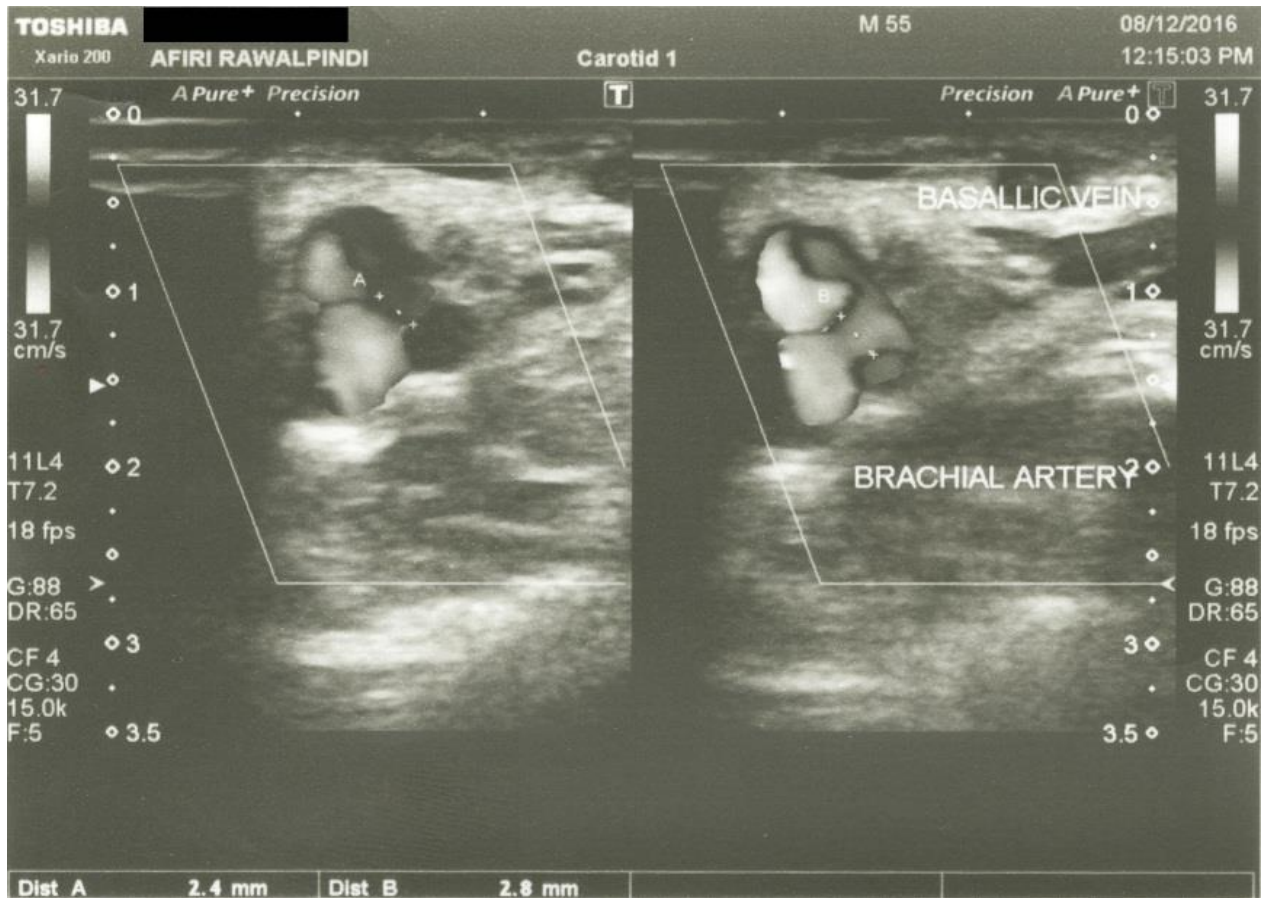
E-mail:
maj.abdulrehman@gmail.com

Cite this Article:
Arshad AR, Islam F, Qayyum M. Iatrogenic brachiobasilic fistula in a hemodialysis dependent patient. J Pioneer Med Sci. 2021;10(1):8-9

Figure 1: Fistula in left arm and needle marks on right arm. The red arrow shows the scar from surgery in the left cubital fossa. Recent puncture marks over the draining vein of the left arm fistula are enclosed in a red circle. Blue arrow points to puncture marks over the right upper arm.

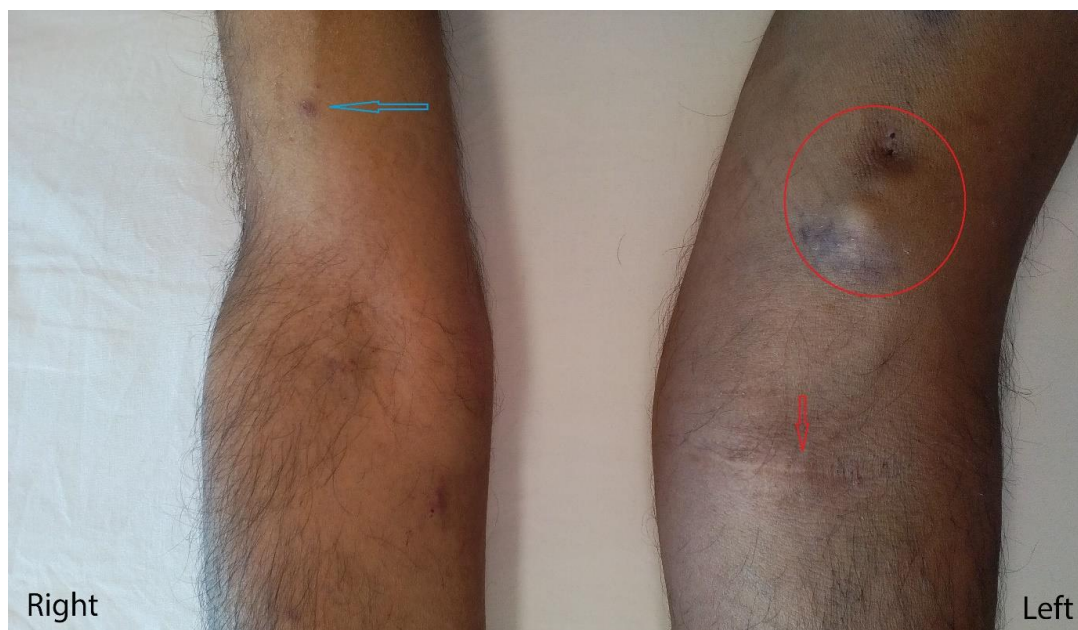

Figure 2: Doppler scan showing the fistula between the right brachial artery and basilic vein



REFERENCES

1. Amira CO, Bello BT, Braimoh RW. A study of outcome and complications associated with temporary hemodialysis catheters in a Nigerian dialysis unit. *Saudi J Kidney Dis Transpl.* 2016;27(3):569–575.
2. Al-Jaishi AA, Liu AR, Lok CE, Zhang JC, Moist LM. Complications of the arteriovenous fistula: a systematic review. *J Am Soc Nephrol.* 2017;28(6):1839–1850.