

Intraparenchymal Brain Malignant Fibrous Histiocytoma

N. Giaj Levra¹, C. Mantovani¹, E. Trevisan², U. Ricardi¹

¹Department of Oncology, Radiation Oncology Unit, University of Torino, S. Giovanni Battista Hospital, Città della Salute e della Scienza, Turin, Italy

²Department of Neuro-Oncology, University of Torino, S. Giovanni Battista Hospital, Città della Salute e della Scienza, Turin, Italy

BRIEF HISTORY

A 60-year-old man, with a history of hypercholesterolemia and left leg deep vein thrombosis, was admitted to hospital following two weeks of headaches and expressive aphasia. Neurological examination confirmed expressive aphasia in the absence of motor, sensory or cranial nerve deficit.

A total body computer tomography (CT) imaging showed a single intraparenchymal lesion with a central necrotic area and peripheral edema in the left temporal lobe. MRI confirmed a single enhancing lesion of 25 mm on the left temporal lobe associated with perilesional edema (Figure 1). Positron emission tomography confirmed that there was no extra-cranial active disease.

A radical left temporal craniotomy was performed and histopathological examination revealed an intraparenchymal mesenchymal tumor compatible with malignant fibrous histiocytoma (MFH). The pathologist described two different histological patterns: spindle cells forming fascicles and large neoplastic cell with

foci of necrosis (Ki67 proliferation index: 70%). Post-operative course was complicated by fever. CT scan detected an infection in the surgical cavity, most likely *Staphylococcus aureus*. Consequently, intravenous antibiotic was administered for 6 weeks. A restaging MRI demonstrated a local recurrence associated with post-infection changes in the left temporal lobe (Figure 2). Despite a greater elapsed time following surgery than is usual (three months compared with an average of one month), adjuvant radiation treatment using 60 Gy in 30 fractions was administered. The patient died 18 months later from focal progressive disease.

DISCUSSION

The incidence of primary intraparenchymal brain MFH is extremely rare and, in literature from 1974, it is reported in less than forty cases [1]. It is often difficult to make a differential diagnosis from other primary brain tumors and radiological presentation, in this case, was compatible with glioblastoma [2]. Standard treatment for intra-

Figure 1: A contrast-enhancing lesion with a central necrotic area is detectable in the left temporal lobe

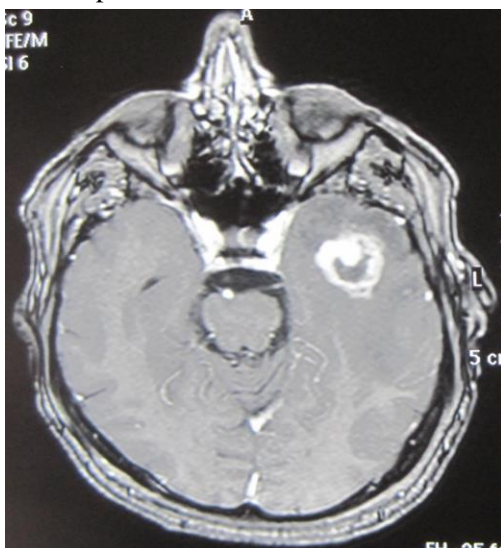
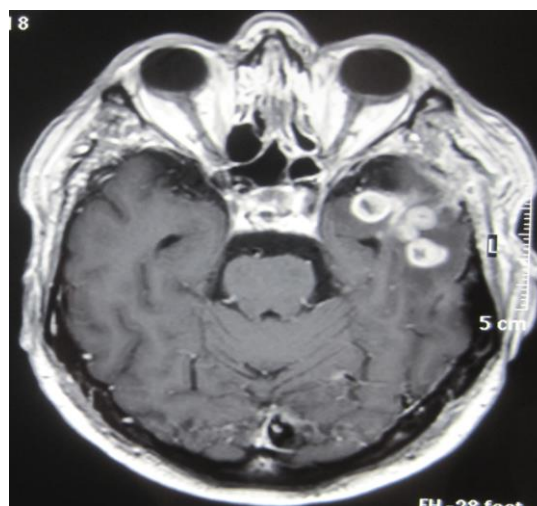

Figure 2: A possible recurrence of disease difficult to differentiate from post-*Staphylococcus aureus* infection is detectable in the left temporal lobe



Conflict of Interest:
None declared

This article has been
peer reviewed.

Article Submitted on: 2nd
July 2013

Article Accepted on: 22nd
October 2013

Funding Sources: None
declared

Correspondence to: Dr
N. Giaj Levra

Address: Department of
Oncology, Radiation
Oncology Unit,
University of Torino, S.
Giovanni Battista
Hospital, Turin, Italy

Email:
gmicco@yahoo.it

Cite this article: Levra
NG, Mantovani C,
Trevisan E, Ricardi U.
Intraparenchymal brain
malignant fibrous
histiocytoma. *J Pioneer
Med Sci.* 2014; 4(1):33-
34

parenchymal MFH is radical resection associated with adjuvant radiotherapy; the efficacy of chemotherapy is still undetermined [3]. In most cases, MFH recurs locally and the overall survival rate is 23% at two years [4].

REFERENCES

1. Mitsuhashi T, Watanabe M, Ohara Y, Hatashita S, Ueno H. Multifocal primary intracerebral malignant fibrous histiocytoma. *Neurol Med Chir* 2004; 44:249-254.
2. Simpson RH, Philips JI, Miller P, Hagen D, Anderson JE. Intracerebral malignant fibrous histiocytoma: A light and electron microscopic study with immunohistochemistry. *Clin Neuropathol* 1986; 5:185-189.
3. Fujimura N, Sugita Y, Hirohata M, Naohisa M, Terasaki M, Tokutmi T, Shigemori M. Primary intracerebral malignant histiocytoma in a child. *Pediatr Neurosurg* 2002; 37:271-274.
4. Akimoto J, Takeda Y, Hasue M, Ito H, Kiguchi E. Primary meningeal malignant fibrous histiocytoma with cerebrospinal dissemination and pulmonary metastasis. *Acta Neurochir (Wien)* 1998; 140:1191-1196.