

Sacral Chordoma and Incidental Renal Oncocytoma: Two Extremely Rare Tumors in One Patient

Seyed Majid Akhavan Hejazi¹, Kumaran Ramakrishnan²

¹Department of Rehabilitation Medicine, Faculty of Medicine, University of Malaya, Kuala Lumpur, Malaysia

A 50-year-old woman presented with a nine month history of episodic non-radiating left buttock pain that initially responded to over-the-counter (OTC) analgesics. However, the pain subsequently progressed to a level where it was not controlled with OTC analgesics leading her to seek medical attention at a primary medical center where she underwent an MRI examination. She was referred to our hospital as her pain started radiating to her left leg and foot and was poorly controlled. Pain was associated with distal weakness and numbness and she was using walking aid for ambulation. She denied any changes in bowel and bladder habits.

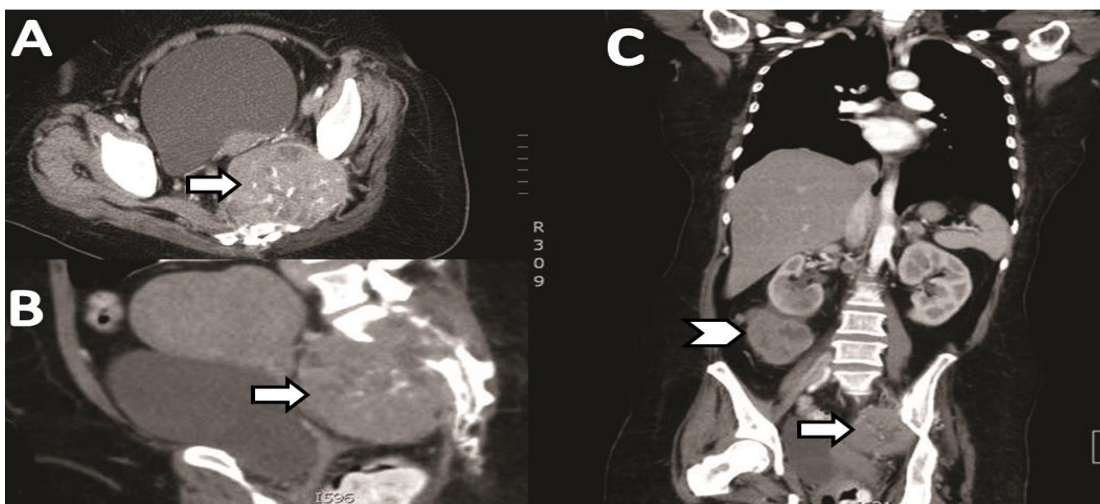
On examination, she was in pain with a positive straight leg raise test on the left side at 40 degrees. There was weakness of the left great toe extension (L5), ankle dorsiflexion (L4) and plantar flexion (S1) with Medical Research Council (MRC) muscle strength of 0/5 in all these muscles. The knee jerk was normal but the

ankle jerk was absent and there was loss of pin-prick sensation over the dermatomal areas of L5, S1 and S2, on the same side. The digital rectal examination revealed a lax anal tone with a weak voluntary anal contraction.

Whereas laboratory studies were not significant, initial pelvic MRI showed a large well-delineated sacral mass. For tumor staging, a computed tomographic scan was performed which showed a mass in the left sacrum and ilium, and a large right kidney lesion with multiple lung metastases (Figure 1). Finally, cytology of the sacral lesion and the renal lesion suggested sacral chordoma and an oncocytoma of renal origin, respectively.

Chordoma is a rare notochordal remnant tumor, but it is the most common pre-sacral malignancy metastasizing (20%) to the lungs [1]. Pain and neurological symptoms are the chief presenting complaints [2]. Oncocytomas are primary benign epithelial renal neoplasms whereby most are incidental findings on radiologic images [3, 4].

Figure 1: (A) Computed tomographic scan of the chest, abdomen and pelvis of a 50-year-old woman with left buttock pain. (B) Axial and sagittal views, showing a mass 8.5(W)×8.4(AP)×9.4(Ht) cm with foci calcification and adjacent bony destruction of the left sacrum (S1-S3) and left ilium (arrows). (C) Coronal view, showing the same mass with a large heterogeneously enhancing exophytic lesion arising from the lower pole of the right kidney measuring 9.4(W)×6.0(AP)×10.6(Ht) cm with a necrotic center (arrowhead), and multiple lung metastases.



Conflict of Interest:
None declared

This article has been
peer reviewed.

Article Submitted on: 7th
July 2013

Article Accepted on: 22nd
December 2013

Funding Sources: None
declared

Correspondence to:
Seyed Majid Akhavan
Hejazi

Address: Department of
Rehabilitation Medicine,
Faculty of Medicine,
University of Malaya,
Kuala Lumpur, Malaysia

Email:
dr.majid.hejazi@gmail.com,
drkumaran@um.edu.my

Cite this article: Hejazi
SMA, Ramakrishnan K.
Sacral chordoma and
incidental renal
oncocytoma: two
extremely rare tumors in
one patient. *J Pioneer
Med Sci* 2014; 4(2):77-
78

Whereas a small percentage of chordoma shows a familial pattern of inheritance [2], oncocytomas usually correlate with chromosomal abnormalities [3]. To the best of our knowledge, the concurrency of chordoma and oncocytoma, both from different embryonic layer origins and without chromosomal abnormality, have not been reported in the literature. In a patient rehabilitation setting such as ours, however, there is incidental concurrency with different specificity of these two tumors and further radiotherapy or chemotherapy will not be effective on patient's functional outcome [5].

Surgery remains the first choice of treatment for both tumors. Although postoperative radiotherapy is recommended for chordoma, the long-term prognosis is generally poor compared to oncocytoma [2, 4]. Pain intensity in chronic cancer diseases correlates neither with tumor type nor with the number, size or location of bone metastases [6]. In this patient, pain was controlled with medications and palliative radiotherapy, as patient was not deemed a suitable candidate for operation.

REFERENCES

1. Hassan I, Wietfeldt ED. Presacral tumors: diagnosis and management. *Clin Colon Rectal Surg* 2009; 22:84-93.
2. Babazadeh S, Broadhead ML, Slavin JL, Choong PFM. An interesting diagnosis for a presacral mass: case report. *Int Semin Surg Oncol* 2009; 6:18.
3. Alamara C, Karapanagiotou EM, Tourkantonis I, Xyla V, Maurer CC, Lykourinas M, et al. Renal oncocytoma: a case report and short review of the literature. *Eur J Intern Med* 2008; 19:e67-9.
4. Fan YH, Chang YH, Huang WJ, Chung HJ, Chen KK. Renal oncocytoma: clinical experience of Taipei Veterans General Hospital. *J Chin Med Assoc* 2008; 71:254-8.
5. Cole RP, Scialla SJ, Bednarz L. Functional recovery in cancer rehabilitation. *Arch Phys Med Rehabil* 2008; 81:623-7.
6. Riccio AL, Wodajo FM, Malawer M. Metastatic carcinoma of the long bones. *Am Fam Physician* 2007; 76:1489-94.