

Blast injuries and Brain Trauma: An Overview

Rowan J.S. Miller¹, Jeffrey V. Rosenfeld²

¹Medical Student V, Monash University, Melbourne, Victoria, Australia

²Professor of Surgery and Neurosurgery, Departments of Surgery and Neurosurgery, The Alfred Hospital, Monash University, Melbourne, Victoria, Australia

ABSTRACT

Bomb explosions frequently cause devastating multiple injuries (polytrauma). Medical students should have an appreciation of the pattern and mechanism of the injuries caused by bomb blast and the early care of the injured. This review focuses on the traumatic brain injury (TBI) caused by bomb blast including the pattern

of injury, the multidisciplinary aspects of the treatment, the surgical principles and the prognosis. The outcomes of severe blast TBI's are generally better than high velocity gunshot wounds to the brain. The best outcomes will occur when well-developed trauma systems are in place.

Keywords: Bomb Explosions; Traumatic Brain Injury; Polytrauma

INTRODUCTION

Bomb explosions are most common in warzones but are also frequently encountered in countries riven with sectarian violence such as Iraq and Syria. Bomb blast injuries are also seen in isolated terrorist attacks such as those that have recently affected Pakistan. Medical students in Pakistan should be familiar with the topic of bomb blast injury and its effects on humans. Bomb blast trauma ranges from mild to extremely severe depending on the energy dissipated by the explosion, the distance of the victim from the epicenter of the blast, the orientation of the victim and the environment in which the blast occurs. Enclosed spaces such as a bus or a subway train create more severe trauma than open space [1].

There has been a ten-fold rise in terrorist attacks over recent decades [2]. The incidence of blast-induced TBI is therefore increasing in civilian populations. These events pose unique challenges for civilian medical services. Hospitals face resource constraints and triage dilemmas in mass casualty situations, and practitioners must contend with the unique surgical challenges blast injuries pose, including extensive tissue devitalization, burns and polytrauma. There are four mechanisms of blast-induced injury. Primary blast injury results from the pressure wave passing through the body causing injury to the internal organs. Secondary blast injury results from fragments of the bomb penetrating the body. Tertiary blast injury is caused by the

energy of the blast, which may physically throw the human body against walls or other fixed structures. Quaternary blast injury represents thermal, chemical or other miscellaneous injuries sustained during the blast [3-5].

OVERVIEW: BLAST INJURY TO THE BODY

Explosions cause an initial high pressure shock wave as the blast radiates outward, followed by a "blast wind" as air is drawn to the original detonation point (Figure 1) [5,6]. This shockwave causes primary blast injury via barotrauma: that is, damage caused by the effects of pressure changes too drastic for the body to accommodate [6]. When a blast wave passes through the human body it causes tissues to oscillate. The degree of pressure that results from the vibrating tissues is determined by an inherent property of the tissue called its *acoustic impedance*. Damage from the shockwave typically occurs at air-fluid interfaces or in gas filled organs because these have large *acoustic impedance mismatches*, subjecting these areas to dynamic pressure changes [7]. Medical personnel should be cognisant of this mechanism, as it explains why the lungs, bowel, and tympanic membranes are very susceptible to primary blast injury [8]. Tympanic membrane rupture is the most common primary blast injury [8]. It occurs at a blast pressure of just 5 pounds per square inch above atmospheric pressure [9]. Tympanic membrane integrity is sensitive to the point of

Conflict of Interest: None declared

This article has been peer reviewed.

Article Submitted on: 5th November 2013

Article Accepted on: 22nd December 2013

Funding Sources: None declared

Correspondence to: Dr Jeffrey V. Rosenfeld

Address: Department of Surgery, Monash University, 6th floor, The Alfred Centre, Melbourne, Australia

E-mail: j.rosenfeld@alfred.org.au

Cite this article: Miller RJS, Rosenfeld JV. Blast injuries and brain trauma: An overview. *J Pioneer Med Sci.* 2014; 4(3):94-99

being a screening tool for blast injury [6] and predictor of prognosis. Rupture of the eardrum results in temporary deafness, as opposed to dislocation of the ossicles or injury to the cochlea; two associated but more severe injuries that result in permanent hearing loss. Blast Lung Injury (BLI) is the single most important prognostic variable in immediate survival [10]. Blast Lung injury may manifest as pulmonary contusions, pulmonary hemorrhage, pneumothorax, alveolar-venous fistulae and air embolism. The first sign is often oxygen desaturation, sometimes in the absence of other signs [6]. Blast injuries to the abdomen present on a spectrum from minor submucosal bleeding to full thickness disruption and perforation. The characteristic lesion is a mural hematoma [11-13]. Delayed perforation may occur up to 14 days after the explosion and is probably ischemia related [12-14]. Rupture of solid abdominal viscera may occur.

Traumatic limb amputations and multiple soft tissue wounds and fractures are also common. The classic appearance of fragment injuries is a small entry wound with severe internal damage from cavitation effect, associated with devitalized tissue and gross contamination [1].

BLAST-INDUCED TRAUMATIC BRAIN INJURY: DEFINITION AND EPIDEMIOLOGY

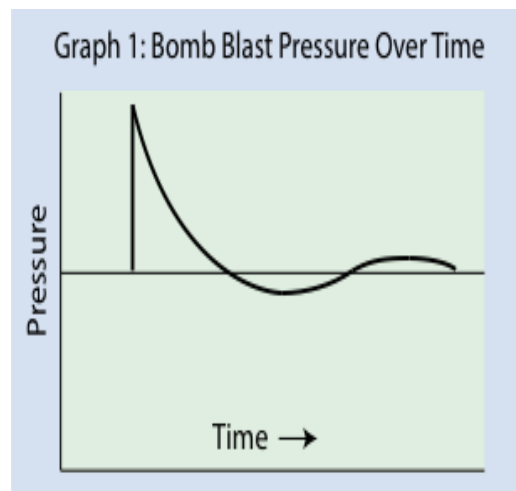
Blast-induced Traumatic Brain Injury is classified into mild, moderate and severe [15]. A Glasgow Coma Scale (GCS) score of 13-15 and loss of consciousness of less than 30 minutes is a mild blast TBI; moderate TBI's have a GCS of 9 to 12; severe TBI's present with a GCS of 3-8 and generally signify life threatening cerebral edema and intracranial hemorrhage.

Large epidemiological studies on TBI's have emerged from the Iraq and Afghanistan military operations, although these studies were not restricted solely to TBI's from blast injury. 9% of 7909 US combat marines [16], and 9.5% of UK marines returning from combat [17] screened positive for mild TBI's. Of 22,203 personnel from US Army Special Operations Commands, Kontos and colleagues found 12.7% had at least one mild TBI [18].

BLAST-INDUCED TRAUMATIC BRAIN INJURY: PATHOLOGY AND PATHOPHYSIOLOGY

The wide range of pathology seen in blast-induc

Figure 1: Bomb Blast pressure over time



-ed TBI includes concussion, brain contusion, petechial hemorrhage, subdural hematoma, intracerebral hematoma, intraventricular hemorrhage, subarachnoid hemorrhage, brain swelling, raised intracranial pressure and penetration of metal and bone fragments into the brain and breaches of the skull resulting in cerebrospinal fluid (CSF) leak [1, 15]

The brain is particularly prone to direct damage from the primary blast injury at CSF-brain interfaces, resulting in bubble formation, cavitation of brain tissues, capillary damage and axonal pathway disruption [15, 19, 20]. The blast wave can also indirectly affect the brain. It causes a rush of blood from the trunk to the brain vasculature, causing high cerebral blood pressure to disrupt the microcirculation and blood brain barrier [21]. Two studies suggest that wearing torso body armor may actually lessen blast-induced brain trauma [22, 23]. The orbits and nasal sinuses may act as an anatomical funnel for the primary blast wave, focusing injury on the orbito-frontal cortex [24]. At a cellular level, blasts cause free-radical mediated oxidative stress, contributing to the injury [25]. Extra cranial and intracranial vascular injury may also occur, including carotid and vertebral artery dissection, rupture and thrombosis or late pseudo aneurysm formation.

Temporally, explosions may immediately cause a short period of apnea accompanied by bradycardia and hypotension, which is believed to reflect the blast waves effect on the brain stem or a vago-sympathetic reflex activated from the chest [9,26,27]. In the first few hours after the blast, brain swelling typically occurs – a combination of cerebral edema and vascular engorgement – but may occur several days after

the injury. At 24-48 hours post injury, Armonda and colleagues found 47.4% of 57 patients with TBI's, mostly from bomb blasts, had traumatic vasospasm which on average lasted two weeks [28].

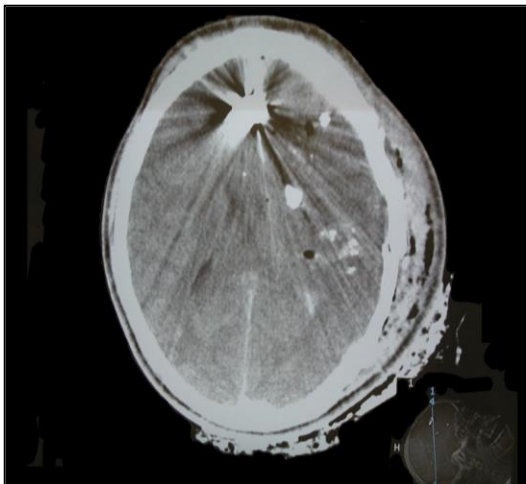
BLAST-INDUCED TRAUMATIC INJURY: DIAGNOSIS

Mild TBI patients typically have a GCS of 13-15, although GCS is a relatively unreliable indicator as many will have a GCS of 15. Both blast and non-blast mild traumatic brain injury can be followed by headaches, cognitive dysfunction, attention difficulties, and impaired balance. The Military Acute Concussion Evaluation (MACE) is a clinical tool for mild traumatic brain injury screening [30]. It is composed of two sections; the patient's history and the Standardized Assessment of Concussion, which is also validated for sports injuries [31]. Eye tracking and balance testing may be useful clinical adjuncts, as balance disturbance results from vestibular and otolith dysfunction [32, 33]

In comparison, moderate or severe TBI typically present with a corresponding GCS of 9-12 and 3-8 respectively. These patients require CT neuroimaging (Figure 2) for investigating the extent of damage and planning surgery, and many require angiography to check for concomitant extra cranial and intracranial vascular injury.

Blast-induced mild TBI often results in normal brain CT's and MRI's. Diffusion tensor imaging which is sensitive for white matter fibre tracking has thus far proven inconsistent as an investigational tool for mild TBI's [34]. PET,

Figure 2: Computed Tomography in Traumatic Brain Injury



functional MRI, serum biomarkers and blast dosimeters placed on combat helmets are current areas of research [35-37].

BLAST-INDUCED TRAUMATIC BRAIN INJURY: EARLY RESUSCITATION

The 'ABC' principles of Advanced Trauma Life Support (ATLS) apply directly to the early resuscitation of the bomb blast victim. Hemorrhage control is required to prevent exsanguination and fractures must be stabilized, as must the cervical spine in suspected neck injury [1]. The patient should be intubated if the GCS is < 9. 'Damage control resuscitation' is practiced to rapidly correct physiologic derangements such as hypotension, hypothermia and acidosis, the "lethal triad". Untreated, these may increase mortality through coagulopathy.

BLAST-INDUCED TRAUMATIC BRAIN INJURY: PRINCIPLES OF SURGERY

'Damage Control surgery' is a priority during initial neurosurgical intervention and is applicable to moderate or severe injuries [1]. Decompressive craniectomies are a pillar of neurosurgical management, and are indicated in patients with a GCS<9, CT evidence of brain swelling, penetrating brain fragments or intracranial hematomas [1,15]. In the case of bilateral hematomas a bilateral craniectomy is required. The craniotomy is normally a large fronto-temporo-parietal flap. After opening the dura, subdural hematomas are removed, and hemostatic control gained from coagulation and tamponade of bleeding vessels. Any superficial penetrating fragments are removed. Lobectomy is considered if there is extensive devitalization of cerebral tissue, and temporal lobectomy may be indicated if there is evidence of upper brain stem compression with a dilated pupil [1]. For patients with a GCS<9 a ventriculostomy (external ventricular drain) with CSF venting will help control the ICP, and if available, an intraparenchymal ICP monitor may also be placed to continuously measure the ICP. The dura must be closed watertight, to avoid CSF leak and secondary infection. The dura over the skull base is particularly prone to breach by penetrating fragments [1]. Scalp closure over the injured area is the goal, as dura and bone should not remain exposed. Secondary operations or complex cranio-facial reconstructions are performed at a later date as, having stabilized the patient, mass casualty situations frequently mean

surgeons must then prioritize other emergency cases. Neurosurgeons, maxillofacial, ear, nose and throat (ENT) and ophthalmological surgeons may all be involved in the repair and reconstruction of complex craniofacial injuries following bomb blast.

MILD BLAST-INDUCED TRAUMATIC BRAIN INJURY: MANAGEMENT

The management of mild presentations focuses on observation, additional blast exposure prevention, and psychological care. American military guidelines state that personnel with mild TBI should not return to the battlefield until there is resolution of concussion, as literature shows that additional brain trauma during this time might result in prolonged recovery or permanent disability [38]. Some soldiers will display symptoms of post-concussive syndrome - headache, fatigue, sensitivity to external stimuli, sleep disturbance and concentration difficulties [39] - for which a double-blinded, placebo controlled study has found acetylcysteine effective [40]. The same principles of management can be applied in the civilian situation.

MILD BLAST-INDUCED TRAUMATIC BRAIN INJURY: PSYCHOLOGICAL SEQUELAE

Patients with mild TBI have an increased risk of post-traumatic stress disorder (PTSD) [41-43]. During studies of US Army Special Operations, Kontos and colleagues noted that PTSD symptoms occurred in 14.6% of participants with mild TBI, and they concluded that PTSD symptoms were more prevalent in patients whose mild TBI was blast related. The researchers also observed a dose-response gradient between number of bomb blasts and mild TBI and PTSD, suggesting that repeated exposures may result in permanent disability [18]. It is not known whether civilian victims of a bomb blast injury show similar rates of PTSD and other mental health issues following bomb blast injury. PTSD has been shown to occur even with amnesia of the original blast incident [41,43]. One possible explanation is that the parts of the brain implicated in PTSD (basal frontal, anterior, and mesial temporal lobes) are vulnerable in bomb blasts [43,44]. In addition, many of the features of PTSD overlap with post-concussive syndrome, making the distinction between the two difficult at times [41]. Chronic pain in blast-induced TBI

patients is also common, and one study of 340 patients found that 42% of blast trauma victims exhibited the triad of chronic pain, PTSD and post-concussive syndrome [45,46].

PROGNOSIS

The prognosis for blast-induced TBI correlates with Glasgow Coma Scale scores on admission [47, 48]. 64% of patients presenting with a GCS between 6 and 8 had attained functional independence at 2 years, double the percentage of patients presenting with a GCS of 3-5 in one study [47]. The mortality for blast-induced TBI is heavily dependent on whether the injury occurs in a military or civilian setting. In a retrospective study [49] of 604 patients, military patients with either an isolated blast-induced TBI or penetrating severe TBI had mortality rates of 7.7% and 5.6% respectively, lower than in patients who sustained similar injuries in a civilian setting (21% and 47.0%). Although this discrepancy is in part because of lower neurosurgical intervention rates in civilian settings, it may also result from the higher rate of gunshot wounds in a civilian setting. Blast-induced TBI patients may show improvements over a 1-2 year period [47, 48]

CONCLUSION

Blast-induced TBI is becoming more common in a civilian setting. Patient presentation varies, dependent on the exact mechanism of injury; primary (barotrauma), secondary (penetration), tertiary (acceleration affects) or quaternary (burns and miscellaneous). The Primary blast wave causes damage to the tympanic membranes, lungs, bowel and in the brain. Blast-induced TBI's are graded into mild, moderate and severe, which roughly correlate with GCS and have different clinical courses. Mild blast-induced TBI's are acutely managed like mild non-blast TBI's. Moderate and severe blast-induced TBI pose a tangible risk to life and are often complicated by poly trauma. In the acute setting decompressive craniotomies are common life-saving interventions, but many patients will require additional surgery once they have been acutely stabilized. Mild TBI has an excellent prognosis, though associated with psychological sequelae. The mortality in severe and moderate blast-induced TBI is influenced by whether the injury is sustained in a military or civilian setting.

REFERENCES

1. Rosenfeld JV. Neurosurgical injury related to terror. In: Shapira SC, Hammond JS, Cole La, eds. *Essentials of Terror Medicine*. New York: Springer, 2009: 313-36
2. Frykberg ER. Medical management of disasters and mass casualties from terrorist bombings: how can we cope? *J. Trauma* 2002; 53: 201-12.
3. Hadden WA, Rutherford WH, Merrett JD. The injuries of terrorist bombing: a study of 1532 consecutive patients. *Br. J. Surg.* 1978; 65: 525-31.
4. Karmy-Jones R, Kissinger D, Golocovsky M. Bomb related injuries. *Mil. Med.* 1994; 159: 536-9.
5. Langworthy MJ, Smith JM, Gould M. Treatment of the mangled extremity after a terrorist blast injury. *Clin. Orthop.* 2004; 422: 88-96.
6. DePalma RG, Burris DG, Champion HR, Hodgson MJ. Blast injuries. *N. Engl. J. Med.* 2005; 352: 1135-42.
7. Guy RJ, Glover MA, Cripps NP. The pathophysiology of primary blast injury and its implications for treatment. Part 1: the thorax. *J. R. Nav. Med. Serv.* 1998; 84: 79-86.
8. Leibovici D, Gofrit ON, Shapira SC. Eardrum perforation in explosion survivors: is it a marker for pulmonary blast injury? *Ann. Emerg. Med.* 1999; 34: 168-72.
9. Jensen JH, Bonding P. Experimental pressure induced rupture of the tympanic membrane in man. *Acta Otolaryngol.* 1993; 113: 62-7.
10. Guy RJ, Kirkman E, Watkins PE, Cooper GJ. Physiological responses to primary blast. *J. Trauma* 1998; 45: 983-7.
11. Cripps NPJ, Glover MA, Guy RJ. The pathophysiology of primary blast injury and its implications for treatment. Part II: the auditory structures and abdomen. *J. R. Nav. Med. Serv.* 1999; 85: 13-24.
12. Cripps NPJ, Cooper GJ. Risk of late perforation in intestinal contusions caused by explosive blast. *Br. J. Surg.* 1997; 84: 1298-303.
13. Waterworth TA, Carr MJT. An analysis for the post-mortem findings in the 21 victims of the Birmingham pub bombings. *Injury* 1975; 7: 89-95.
14. Katz E, Ofek B, Adler J et al. Primary blast injury after a bomb explosion in a civilian bus. *Ann. Surg.* 1989; 209: 484-8.
15. Rosenfeld JV, McFarlane AC, Bragge MD et al. Blast-related traumatic brain injury. *Lancet Neurology* 2013; 9: 882-893.
16. Drake AI, Meyer KS, Cessante LM, et al. Routine TBI screening following combat deployments. *NeuroRehabilitation* 2010;26:183-89.
17. Rona RJ, Jones M, Fear NT, et al. Mild traumatic brain injury in UK military personnel returning from Afghanistan and Iraq: cohort and cross-sectional analyses. *J Head Trauma Rehabil* 2012;27:33-44.
18. Kontos AP, Kotwal RS, Elbin R, Lutz RH, Forsten RD, Benson PJ. Residual effects of combat-related mild traumatic brain injury. *J Neurotrauma* 2013;30: 680-86.
19. Nakagawa A, Manley GT, Gean AD, et al. Mechanisms of primary blast-induced traumatic brain injury: insights from shock-wave research. *J Neurotrauma* 2011; 28:1101-19
20. Wolf SJ, Bebartha MVS, Bonnet CJ, Pons PT, Cantrill SV. Blast injuries. *Lancet* 2009; 374:405-15
21. Chen Y, Huang W. Non-impact, blast-induced mild TBI and PTSD: concepts and caveats. *Brain Inj* 2011;25:641-50
22. Long JB, Bentley TL, Wessner KA, Cerone C, Sweeney S, Bauman RA. Blast overpressure in rats: recreating a battlefield injury in the laboratory. *J Neurotrauma* 2009; 26: 827-40.
23. Koliatsos VE, Cernak I, Xu L, et al. A mouse model of blast injury to brain: initial pathological, neuropathological, and behavioral characteriation. *J neuropatholo Exp Neurol* 2011; 70: 399-416
24. Elder GA, Mitsis EM, Ahlers ST, Christian A. Blast-induced mild traumatic brain injury. *Psychiatr Clin North Am* 2010;33:757-81
25. Elsayed NM. Toxicology of blast overpressure. *Toxicology* 1997; 121: 1-15.
26. Axelsson H, Hjelmqvist H, Medin A et al. Physiological changes in pigs exposed to a blast wave from a detonating high-explosive charge. *Mil. Med.* 2000; 165: 119-26. 18.
27. Sapsford W. Penetrating brain injury in military conflict; does it merit more research? *J. R. Army Med. Corps* 2003; 149:5-14.
28. Armonda RA, Bell RS, Vo AH, Ling G, De Graba TJ, Crandall B, Ecklund J, Campbell WW. Wartime traumatic cerebral vasospasm: recent review of combat casualties. *Neurosurgery* 2006;59,1215-1225. *Neurosurgery* 2006;59
29. Marion DW, Curley KC, Schwab K, Hicks RR. Proceedings of the military mTBI Diagnostics Workshop, St. Pete Beach, August 2010 *J Neurotrauma* 2012;72:673-81
30. French LMM, Baggett M. The Military Acute Concussion Evaluation (MACE). *J Spec Oper Med* 2008; 8: 68-77
31. McCrory P, Meeuwisse WH, Aubry M, et al. Consensus statement on concussion in Sport held in Zurich, November 2012. *Br J Sports Med* 2013;47:250-58
32. Maruta J, Suh M, Niogi SN, Mukherjee P, Ghajar J. Visual tracking synchronization as a metric for concussion screening. *J Head Trauma Rehabil* 2010;25:293-305.
33. Guskiewicz KM. Balance assessment in the management of sport-related concussion. *Clin Sports Med* 2011;30:89-102
34. Leven HS, Wilde E, Troyanskaya M et al. Diffusion tensor imaging of mild to moderate blast-related traumatic brain injury and its sequelae. *J Neurotrauma* 2010; 27: 683-94
35. Francati V, Vermetten E, Bremner JD. Functional neuroimaging studies in posttraumatic stress disorder: review of current methods and findings. *Depress Anxiety* 2007;24:202-18
36. Jeter CB, Hergenroeder GW, Hylin MJ, Redell JB, Moore AN, Dash PK. Biomarkers for the diagnosis and prognosis of mild traumatic brain injury. *Concussion. J Neurotrauma* 2012; 30:657-70,
37. Duckworth JL, Ling GSF, Rodgers J. Blast gauge: quantifying exposure during an improvised explosive device attack. *Neurocrit Care* 2012;3:107.
38. US Veteran's Association, US Department of Defense. Clinical practice guidelines for management of concussion/mild traumatic brain injury, 2009. <http://www.rehab.research.va.gov/jour/09/46/6/pdf/cpg.pdf> (accessed September 2, 2013)
39. Bohnen J, Jolles J. Neurobehavioural aspects of postconcussive symptoms after mild head injury. *J Nerv Ment Dis* 1992;180:683-92
40. Hoffer ME, Balaban C, Slade MD, Tsao JW, Hoffee B. Amelioration of acute sequelae of blast-induced mild traumatic brain injury by N-acetyl cysteine: a double-blind, placebo controlled study. *PLoS One* 2013; 8:e54163.
41. Bryant R. Post-traumatic stress disorder vs traumatic brain injury. *Dialogues Clin Neurosci* 2011;13:251-62.
42. Rosenfeld JV, Ford NL. Bomb blast, mild traumatic brain injury and psychiatric morbidity: a review. *Injury* 2010;41:437-43

43. Vasterling JJ, Verfaellie m, Sullivan KD. Mild traumatic brain injury and posttraumatic stress disorder in returning veterans: perspectives from cognitive neuroscience. *Clin Psychol Rev* 2009; 29:674-84
44. Hoffman SW, Harrison C. The interaction between psychological health and traumatic brain injury: a neuroscience perspective. *Clin Neuropsychol*. 2009;23:1400-15
45. Gironde RJ, Clark ME, Ruff RL, et al. Traumatic Brain Injury, polytrauma, and pain: challenges and treatment strategies for the polytrauma rehabilitation. *Rehabil Psychol* 2009;54:247-58
46. Ruff RL, Ruff SS, Wang XF. Headaches among Operation Iraqi Freedom/Operation Enduring Freedom veterans with mild traumatic brain injury associated with exposures to explosions. *J Rehabil Res Dev* 2008; 45: 697-702.
47. Ecker RD, Mulligan LP, Dirks M, et al. Outcomes of 33 patients from the wars in Iraq and Afghanistan undergoing bilateral or bicompartamental craniectomy. *J Neurosurg* 2011; 115:124-29.
48. Wiesbrod AB, Rodriguez C, Bell R, et al. Wartime traumatic cerebral vasospasm: recent review of combat casualties. *Neurosurgery* 2006;59:1215-25.
49. DuBose JJ, Barmparas G, Inaba K, et al. Isolated severe traumatic brain injuries sustained during combat operations: demographics, mortality outcomes, and lessons to be learned from contrasts to civilian counterparts. *J Trauma* 2011;70:11-16.