

Cavitary Pulmonary Tuberculosis in an Infant: A Diagnostic Dilemma

Niranjan Kumar Sit¹, Supriya Sarkar², Arnab Maji³, Debraj Jash³

¹Assistant Professor, Department of Pulmonary Medicine, NRS Medical College, Kolkata, India

²Professor, Department of Pulmonary Medicine, NRS Medical College, Kolkata, India

³Post-graduate trainee, Department of Pulmonary Medicine, NRS Medical College, Kolkata, India

ABSTRACT

Cavitary pulmonary tuberculosis (TB) is extremely rare in infancy. Cavitation in lung in an infant usually suggests the diagnosis of staphylococcal pneumonia or congenital anomaly. Here we are reporting a 7 month, BCG vaccinated infant who presented with high-grade fever and cavitation on the chest x-ray. Reverse contact tracing did not

reveal TB in parents or close relatives. We established the diagnosis of tuberculosis by demonstrating acid-fast bacilli in his gastric aspirate by smear and culture. We suggest that even in absence of suggestive history of TB, early morning gastric aspirate should be examined in all cases of non-resolving cavities in infants.

Keywords: Tuberculosis; Infant; Cavity; Gastric lavage

INTRODUCTION

Cavitary lung diseases in infants are usually due to infections particularly by staphylococcus species or due to developmental abnormalities such as pulmonary vascular anomaly, congenital diaphragmatic hernia, pulmonary sequestrations etc. Cavities in tuberculosis (TB) usually occur in post-primary and sometimes in progressive primary TB which are rare in infancy and early childhood[1,2]. Only few cases of cavitary TB are reported from pediatric centres in India[1,3]. We are reporting a case of cavitary pulmonary tuberculosis in a 7-month old infant.

CASE REPORT

A 7-month old baby boy was brought to hospital with intermittent high grade fever and cough for past 2 months. There was no clinical improvement despite treatment with intravenous antibiotics including amoxicillin-clavulanic acid(100 mg/kg/day in divided doses for 7 days), ceftriaxone (100 mg/kg/day in divided in two doses for 7 days), linezolid (30 mg/kg/day in divided doses for 2 weeks), vancomycin (60 mg/kg/day in 4 divided doses for 7 days) and meropenem (60 mg/kg/day in divided doses for 5 days) by local pediatricians. Child had normal vaginal delivery with uneventful pre-natal period and birth weight was 2.85 kg. The child had received all vaccines as per National Immunisation Schedule including BCG.

Examination revealed the baby was malnourished with weight (5 kg), length (55 cm) and both were below 3rd percentile of normal according to World Health Organisation (WHO) standard. The child was tachypneic (respiratory rate was 35/minute) and febrile (102^oF). There was no significant lymphadenopathy or organomegaly. Examination of the respiratory system revealed intercostal retractions, bilateral crepitations and high pitched bronchial breath sound over left infraclavicular area. His peripheral blood showed haemoglobin 8.7 g/dl, total leukocyte count 12000/mm³ with neutrophils 50%, lymphocytes 47% and eosinophil 3%. His chest x-ray showed presence of a large cavity in the left upper zone, consolidation in the left lower zone and non-homogenous opacity in the right upper zone [Figure1]. Ultrasonography (USG) of whole abdomen was normal. High-resolution computed tomography (HRCT) of thorax revealed patchy consolidations in both lung fields and a large cavity in the left upper lobe [Figure2]. We aspirated his first morning gastric content through a paediatric Ryle's tube and sent the sample for acid-fast bacilli (AFB) smear and mycobacterial BACTEC culture. Tubercle bacilli were identified under fluorescent microscopy. Reverse contact tracing of his parents and close relatives by chest x-ray (CXR) and sputum for AFB was negative. Gynaecological examination and USG whole abdomen of the mother did not reveal any abnormality. We started category 1 anti-

Conflict of Interest: None declared

This article has been peer reviewed.

Article Submitted on: 25th October 2013

Article Accepted on: 1st January 2014

Funding Sources: None declared

Correspondence to: Dr Arnab Maji

Address: Department of Pulmonary Medicine, NRS medical College, Kolkata, India

Email: drarnabmaji@gmail.com

Cite this Article: Kumar N, Sarkar S, Maji A, Jash D. Cavitary pulmonary tuberculosis in an infant: a diagnostic dilemma. *J Pioneer Med Sci.* 2014; 4(3): 112-114

Figure 1: Chest x-ray (PA view) showing consolidation with a large cavity in the left upper zone



tubercular therapy drugs (ATT) with daily isoniazid 50mg, rifampicin 50mg, pyrazinamide 125 mg, ethambutol 75mg for 2 months and isoniazid 50mg, rifampicin 50mg for last 4 months month. Fever subsided after 7 days of ATT and we discharged the child after 10 days in stable condition. Subsequently report of mycobacterial BACTEC culture came as positive and showed growth of *Mycobacterium tuberculosis*. At follow up after 8 weeks of ATT therapy, the child was doing well, asymptomatic and had radiological improvement of follow-up chest x-ray [Figure 3].

DISCUSSION

Infants, unlike adults, frequently present with unusual manifestations of TB and the diagnosis of TB is delayed or even missed. Cavity due to pulmonary tuberculosis in infancy is extremely rare but may occur as a consequence of progressive pulmonary TB in infancy which is believed to be a result of poor host defence responsible for multiplication of tubercle bacilli. Ultimately primary focus progresses to form area of consolidation. Later, the caseous areas in the lesion liquefies by proteolytic enzymes liberated from dead neutrophils and the liquid material discharges into bronchus forming cavity, known as primary cavitating tuberculosis (PCT) [1,4]. The incidence of PCT is now increasing in African and Indian children than children of western countries[1,4,5]. Early tuberculation, malnutrition and measles are the postulated causes of the epidemiological differences[1]. In a series of 75 cases of children younger than 2 years of age, Maniar et al. described five cases of cavitary TB in infants younger than 3 months of age with the youngest being 45 days [1].As per literature, BCG vaccination lowers the risk of progressive primary tuberculosis [6,7].Therefore BCG vaccination reduces the risk of PCT also.

Figure 2: High resolution computed tomogram showing presence of large in the upper lobe along with patchy areas of consolidation in right upper and middle lobe.

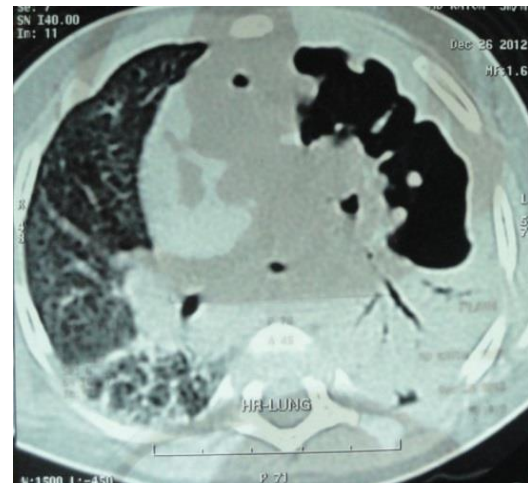
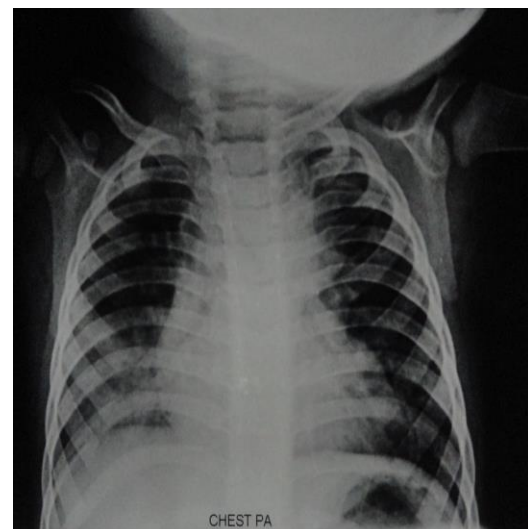


Figure 3: Follow up Chest x-ray (PA view) after 8 weeks of ATD therapy showing resolution of consolidation and cavity



We excluded congenital TB as the baby did not fulfill the criteria (appearance of lesion in the first week of life, primary hepatic complex or caseating hepatic granuloma, TB infection of placenta or the maternal genital tract and exclusion of possibility of post-natal transmission) proposed by Cantwell et al for the diagnosis of congenital TB[8]. Maternal genital TB was also excluded by gynaecological examination and USG whole abdomen of mother. Staphylococcal infection was ruled out on the basis of absence of response to anti-staphylococcal antibiotics and negative blood culture. HIV sero-negativity and localisation of infection in the form of cavity formation ruled out immune-compromisation in our case.

Our case is unique as PCT by itself is an extremely rare entity in infancy. Moreover, absence of extra-pulmonary TB lesions, absence of history of contact with active TB cases and history of BCG vaccination made the diagnosis of PCT difficult.

CONCLUSION

Even in absence of history of contact, typical radiological pattern, extra-pulmonary involvement and positive tuberculin test clinicians should not rule out TB as a possibility and should perform early morning gastric lavage to confirm or to rule out TB in all non-resolving pneumonias during infancy.

REFERENCES

1. Maniar BM. Cavitating pulmonary tuberculosis below age of 2 years. *Indian Pediatr.* 1994;31:181-90.
2. Harris VJ, Duda F, Langer SS, SCHAUF V. Cavitory tuberculosis in children. *J Pediatr.* 1977;90:660-1.
3. Vijayasekaran D, Selvakumar P, Balachandran A, Elizabeth J, Subramanyam L, Somu N. Pulmonary cavitory tuberculosis in children. *Indian Pediatr.* 1994;31:1075-8.
4. Aderole WI. Radiological patterns of pulmonary tuberculosis in Nigerian children. *Tubercle* 1980;61:157-63.
5. Frieman I, Geefhuysen J, Solomon A. The radiological presentation of pulmonary tuberculosis in children. *S Afr Med J* 1975;49:1703-6.
6. Packe GE, Innes JA. Protective efficacy of BCG vaccination in infant Asians. A case control study. *Arch Dis Child* 1988;63:277-81.
7. Chadha R, Tripathi R, Singh D, Roy Choudhury S. Extensive unilobar primary pulmonary tuberculosis in an infant: A diagnostic dilemma. *J Indian Assoc Pediatr Surg* 2005;10:52-4.
8. Cantwell MF, Shehab ZM, Costello AM, Sands L, Green WF, Ewing EP Jr, et al. Brief report: congenital tuberculosis. *N Engl J Med* 1994;330:1051-4.