

The Human Mandible Shattered to a Hundred Pieces: A Disastrous Consequence of Firearm Injury

Abdul Rehman¹, Noor Ul-Ain Baloch¹, Muhammad Awais²

¹Teaching Associate, Department of Biological & Biomedical Sciences, Aga Khan University, Karachi, Pakistan

²Resident, Department of Radiology, Aga Khan University Hospital, Karachi, Pakistan

ABSTRACT

Firearm injuries can lead to grave consequences, especially if suffered to the facial region. Patients who survive these injuries have an enduring impact on their quality of life. In this article, we present a case of a 35-year-old police officer who suffered a firearm injury to his face after being attacked by bandits. He was subsequently managed at our hospital with

multiple procedures. At one-year follow-up visit, he was found to have major depressive disorder, facial deformity, difficulty chewing chewing solid foods and inability to resume his job. We describe how firearm injuries in the facial region have profound psychological and socioeconomic implications for the patient, extending wider than the physical damage and are easily

Keywords: Firearm injuries; Major Depressive Disorder; Deformity

INTRODUCTION

Firearm injuries represent an important source of morbidity and mortality throughout the world [1]. Such injuries if suffered to the facial region can have grave consequences [2]. In some of these cases, patients do not survive [3], but in those cases where the patients remain alive, the quality of life becomes severely relegated [4]. Such patients often suffer long-term disability and cosmetic deformity, which can lead to social withdrawal. If the victim is the bread-winner for the family, it can have a major impact on the economic status of the family. Moreover, post-traumatic stress disorder, major depressive disorder, and other psychiatric illnesses can also develop in such patients. We present a case of a young man who suffered a firearm injury to the face with complete comminution of mandible. We also highlight some of the physical, psychiatric, and economic implications to the patient as a consequence of this injury.

CASE REPORT

A 35-year-old police officer was brought to the emergency department after he was attacked by a group of bandits and suffered a firearm injury to the side of his face. On examination, there was profuse bleeding from the left side of his mouth

along with obvious deformity of the face and a large hematoma in the left side of the neck. Intravenous access was established, blood samples were drawn, fluid therapy was commenced, and blood products were arranged. Due to impending airway obstruction, orotracheal intubation was performed following rapid sequence induction. Trauma rush call was generated and otolaryngology and maxillofacial surgery teams joined the surgical team. Packing of oral and facial wounds was done and broad-spectrum antibiotics were instituted as prophylaxis against gram-positive cocci, gram-negative rods, and anaerobes. A computed tomography (CT) scan of the head and neck with 3D facial reconstruction was obtained as shown in Figure 1. This revealed a comminuted fracture of the mandible along with dislocation of left temporomandibular joint, multiple metallic shrapnels and fractures of hard palate, left pterygoid plate, zygomatic arch, and the walls of maxillary antrum. Patient was taken to the operating room where tracheostomy was performed, thorough debridement of facial, buccal and oral wounds was done, tongue lacerations were repaired and bismuth iodoform paste packs were placed. Patient was initially managed in high-dependency unit with close monitoring. Gradually, patient's condition improved and oral iodoform packs were

Conflict of Interest: None declared

This article has been peer reviewed.

Article Submitted on: 20th May 2014

Article Accepted on: 17th August 2014

Funding Sources: None declared

Correspondence to: Dr Abdul Rehman

Address: Department of Biological and Biomedical Sciences, Aga Khan University, Karachi, Pakistan

E-mail: jsmawais@yahoo.com

Cite this Article: Rehman A, Baloch NUA, Awais M. The human mandible shattered to a hundred pieces: a disastrous consequence of firearm injury. *J Pioneer Med Sci* 2014; 4(4): 171-173

eventually removed. Maxillofacial surgery team performed debridement and fixation of mandibular fragments along with dental extraction and filling. Patient's tracheostomy was subsequently decannulated and the patient was started on a liquid diet.

At one-year follow-up visit, the patient had facial deformity along with difficulty in taking solid foods. He no longer enjoyed eating his food as he finds himself struggling to chew solid food properly. Furthermore, he did not resume his job as a police officer as the sight of his uniform brought back flashbacks of the incident. This led to a substantially decreased income for the family as a whole, compounding their economic problems. He also reported having a low mood, decreased self-esteem, and feelings of guilt. He avoided looking in the mirror because of his deformed face. These symptoms suggested the development of major depressive disorder, for which he was advised to seek psychiatric consultation. Suffice to say, the firearm injury suffered to the face resulted in significant physical, socioeconomic and psychological implications for the patient.

DISCUSSION

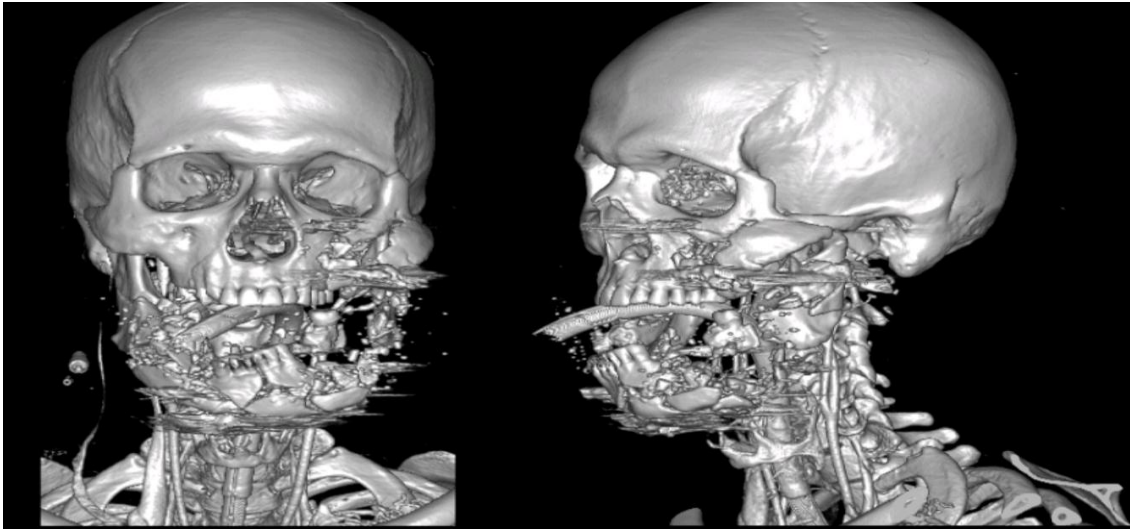
The consequences of firearm injuries to the face are determined by a number of factors including the type of weapon used, distance to traverse and trajectory of the bullet [2]. Homicide is often the underlying motive behind such injuries, as seen in this case [1]. Such injuries have pervasive and adverse implications for the patient extending wider than the physical damage. We shall now discuss the implications of such injuries serially.

Physical Implications: The physical complications of firearm injuries to the face can be broadly classified on the basis of temporality (immediate vs. delayed) or site (local vs. systemic). Local immediate complications of firearm injuries to the face include airway compromise, injury to the cervical spinal cord, soft tissue and bony injuries, severe hemorrhage, and neurologic damage [5]. Immediate systemic complications include rhabdomyolysis, hyperkalemia, acute renal failure and hypovolemic shock. Delayed local complications that are recognized include skin infection, osteomyelitis, disfiguring scars, temporomandibular joint dysfunction, salivary fistula, oroantral fistula, CSF fistula, cranial nerve palsies, hearing loss and anosmia [6].

Psychological implications: While the physical complications of such injuries are very apparent, the intangible psychiatric impact on the patient must not be overlooked. The first reaction of the patient to such an incident is often suppression of the event, though dissociation may also be seen in some cases. Patient often have anxiety, restlessness, insomnia and flashbacks of the incident. A general feeling of insecurity may surround patients and clutter their thoughts. These symptoms are termed as "acute stress reaction" if they last for 24 hours. If the symptoms develop three or more days after the event and last for about a month, they are called "acute stress disorder." For a diagnosis of post-traumatic stress disorder, symptoms of avoidance and re-experiencing the incident occur after the initial injury and persist for more than one month with significant impairment and/or clinical distress [7]. Major depressive disorder can also develop in such patients and manifests with symptoms of anhedonia, feeling of guilt, low mood, crying spells, disturbed sleep, decreased appetite, psychomotor retardation and even suicidal ideations. Propensity to develop major depressive disorder in such patients is a consequence of the cosmetic deformity resulting from excessive soft tissue injury to the face. Moreover, patients often have temporomandibular joint dysfunction with resultant difficulty in chewing food and carrying out activities of daily living. It is important for surgeons and physicians to recognize the psychiatric complications of such injuries as they are easily overlooked in the midst of managing physical complications.

Socioeconomic implications: As doctors, we often perceive patients as collections of symptoms and disorders which we are adept at managing. However, patients are much more than that; they are living members of societies and families and the impact of such injuries often extends to their families. In the health system of Pakistan where health insurance is not routinely provided, the whole cost of treatment has to be paid out of pocket by the patients' families. This scenario is even worse in cases where the breadwinner of the family has suffered the injury and additional cost has to be borne in the face of reduced income (due to absence from work) [8]. Presently, reconstructive procedures to fully restore facial symmetry and function are not widely available. Even at the tertiary care centers of Pakistan, the long-term outcome for such patients seems dismal. Therefore, it is important

Figure 1: Computed tomography (CT) scan of the head and neck with 3D facial reconstruction



to prevent and reduce the incidence of such injuries [1, 3].

CONCLUSION

Firearm injuries suffered to the facial region have profound physical, psychiatric and socioeconomic implications for patients. In a resource-limited country where reconstructive procedures are not widely available, it is important to prevent and decrease the incidence of such injuries.

REFERENCES

1. Shah MM, Ali U, Zaman F, Khan D, Seema N, Jan A, et al. Morbidity & mortality of firearm injury in Peshawar region. *J Ayub Med Coll Abbottabad* 2008; 11:499-502.
2. Bhatti MA, Rana MA, Malik AR, Khalid AM. Firearm injuries: a study of 150 cases. *Pak J Med Health Sci* 2012; 6:438-40.
3. Bashir MZ, Malik AR, Rana PA, Malik SA, Shaheen MA, Khokhar JI, et al. Firearm related deaths in Lahore: a need for efficient emergency services. *Ann King Edward Med Uni* 2001; 7:102-5.
4. Orthopoulos G, Sideris A, Velmahos E, Troulis M. Gunshot wounds to the face: emergency interventions and outcomes. *World J Surg* 2013; 37:2348-52.
5. Hussain Ch T, Tajammul N, Bhatti MA, Hanif S. Firearm injuries – a study of 110 cases. *Ann King Edward Med Uni* 2005; 11:499-502.
6. Pereira C, Boyd JB, Dickinson B, Putnam B. Gunshot wounds to the face: level I urban trauma center: a 10-year level I urban trauma center experience. *Ann Plast Surg* 2012; 3:419-31.
7. Kendrick D, Vinogradova Y, Coupland C, Mulvaney CA, Christie N, Lyons RA, et al. Recovery from injury: the UK burden of injury multicentre longitudinal study. *Inj Prev* 2013; 19:370-81.
8. Jamali A, Ghulamullah S, Qureshi I, Mehboob G. Human cost of political violence. *J Pak Med Assoc* 2000; 50:25-9.