

# Bilateral Psoas Abscess with Extension to Flanks through Iliac Bone Erosion

Vivek Sharma<sup>1</sup>, Ravinder Singh<sup>1</sup>, Amit Mittal<sup>2</sup>, Anu Nagpal<sup>3</sup>

<sup>1</sup>Department of Orthopedics, M.M. Institute of Medical Sciences and Research, Mullana, Haryana, India

<sup>2</sup>Department of Radiodiagnosis, M.M. Institute of Medical Sciences and Research, Mullana, Haryana, India

<sup>3</sup>Department of Gynecology and Obstetrics, M.M. Institute of Medical Sciences and Research, Mullana, Haryana, India

## ABSTRACT

Spinal tuberculosis is common in endemic regions. Psoas abscess associated with lumbosacral tuberculosis is a common finding in long standing cases. But vague symptoms and signs make the clinical diagnosis of psoas abscess with tuberculous spondylodiscitis a challenge. A 22-year-old married female presented with low backache, anorexia and bilateral swellings in the flank regions. The swellings extended to the upper medial quadrant of the buttocks bilaterally. Abdominal ultrasonography showed bilateral psoas abscesses above inguinal ligaments and extending into buttocks bilaterally after iliac bone erosion.

Keywords: Psoas abscess; Buttock abscess; Iliac bones

Magnetic resonance images showed diffuse spondylodiscitis from L1 to S1 and bilateral psoas abscesses, erosion of the iliac bones and a large subfascial abscess over the gluteal muscles. The communication of the buttock abscess into the retroperitoneum and with the psoas abscess was evident. Operative drainage of abscesses was performed and histological examination showed caseous necrosis confirming the clinical diagnosis of tuberculosis. Anti-tuberculous therapy was started and continued for 12 months with complete recovery.

## INTRODUCTION

Spinal tuberculosis is common in endemic regions [1-3]. The psoas muscle is a retroperitoneal muscle that originates from the lateral borders of the 12th thoracic to fifth lumbar vertebrae, and ends as a conjoint tendon with iliacus into the lesser trochanter. [4]. Psoas abscess, first described in 1881 by Mynter [5], is a collection of pus in the psoas compartment, and can be primary or secondary. The long standing vague symptoms and signs make the clinical diagnosis of tuberculous spondylodiscitis with psoas abscess a challenge [1, 3]. We report a unique case of extensive lumbosacral tuberculous spondylodiscitis accompanied by bilateral psoas abscess, which presented as a bilateral soft-tissue flank mass beneath the skin, after eroding the iliac bones. Although psoas abscess due to spinal tuberculosis has been described, bilateral psoas abscess with such presentation is rare.

Here we present three cases of TD that we encountered at our centre from May 2010 to April 2013 and provide a review of published literature of this rare form of osteo-articular

tuberculosis.

## CASE REPORT

A 22-year-old married female presented with progressively worsening six months history of low backache, three month history of anorexia and low-grade nocturnal fever, one month history of weight loss and 2 week history of painful bilateral flank swellings. The swellings extended into the upper medial quadrant of the buttocks measuring 10 cm x 7 cm (right side) and 7 cm x 4 cm (left side) (Figure 1). Lumbar lordosis was obliterated with paraspinal muscle spasm but neurological examination was intact. Hip joints were normal without any pseudoflexion deformity. Blood tests showed white blood cell count of 9,200/mm<sup>3</sup>. ESR was 84mm in 1<sup>st</sup> hour and C-reactive protein level was 10.14 mg/dl. Aspirates from the swellings were sent for culture and sensitivity, cytology, gram and Ziehl-Neelsen staining. Abdominal ultrasonography showed bilateral psoas abscesses extending into buttocks bilaterally after eroding through iliac bones. Magnetic resonance (MR) images revealed diffuse spondylodiscitis from L1 to S1

Conflict of Interest: None declared

This article has been peer reviewed.

Article Submitted on: 6<sup>th</sup> May 2014

Article Accepted on: 20<sup>th</sup> July 2014

Funding Sources: None declared

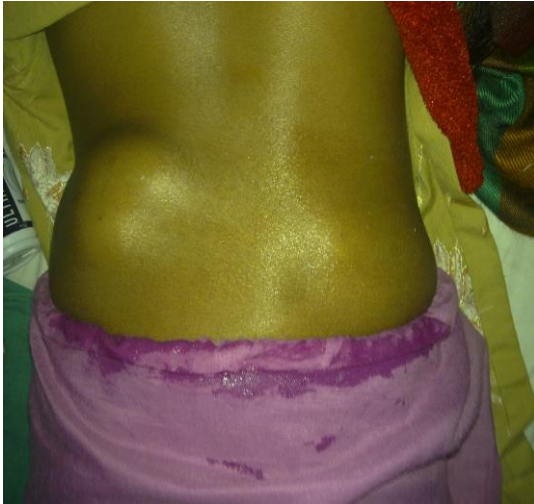Correspondence to: Dr Vivek Sharma

Address: Department of Orthopedics, M.M. Institute of Medical Sciences and Research, Mullana, Haryana, India

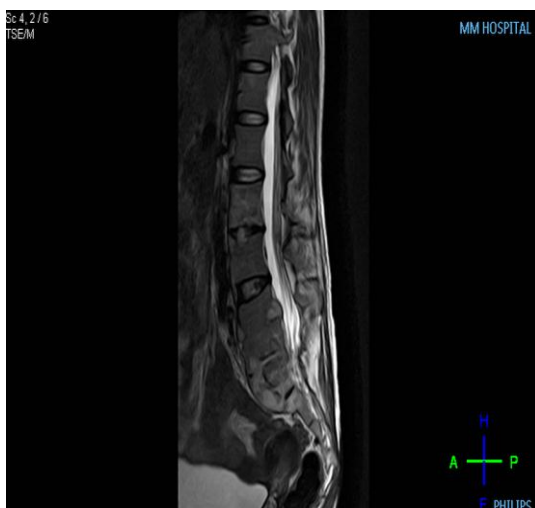
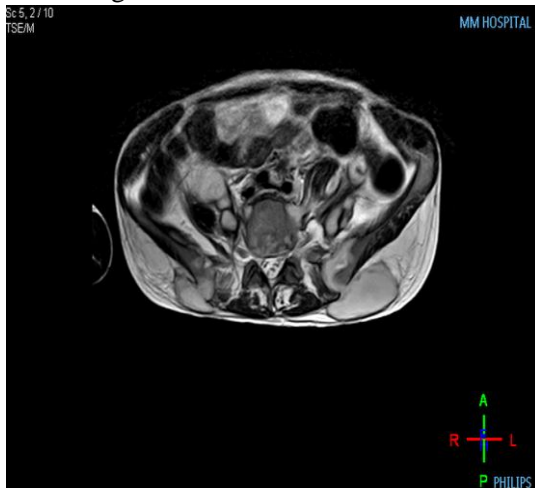
Email: [sharmavivek1979@yahoo.com](mailto:sharmavivek1979@yahoo.com)

Cite this Article: Sharma V, Singh R, Mittal A, Nagpal A. Bilateral psoas abscess with extension to flanks through iliac bone erosion. *J Pioneer Med Sci* 2014; 4(4):165-168

**Figure 1:** Clinical image showing bilateral flank swellings



**Figure 2A and 2B:** MRI images showing bilateral psoas abscess perforating through iliac wings



and confirmed bilateral psoas abscesses, eroding through iliac bones and presenting as large subcutaneous abscess over the gluteal muscles. The communication of the buttock abscess into the retro peritoneum and the psoas abscess was evident (Figure 2A and 2B). There was no involvement of the adjacent organs such as female genitalia, kidney, ureter, and bowel. Both abscesses were drained surgically and specimens were sent for further examination. However, results of the ordinary bacterial or fungal culture were negative. Cytology for malignant cells was also negative and histological examination revealed caseous necrosis implying tuberculosis. Patient was started on anti-tubercular treatment and discharged home for outpatient follow-up. Anti-tubercular therapy was continued for 12 months and patient had complete recovery.

## DISCUSSION

Psoas abscess is rare [6, 7], and that presenting as an extrapelvic extension is even more rare. Psoas abscess eroding the ilium bilaterally and presenting as an extrapelvic extension has not been reported. However, psoas abscess that extended over the iliac wing and presented as a flank or buttock abscess has been reported in medical literature [8, 9, 10-13]. Although the worldwide incidence was considered to be only 12 cases per year [6, 7], psoas abscess is more frequently diagnosed and reported with the advent of computed tomography (CT) and MR imaging [7, 14]. Psoas abscess is considered primary if the cause is hematogenous from a distant site, and secondary if there is a continuous infectious source from vertebrae, pancreas, kidney, ureter, appendix, bowel or hip joint [6, 7, 15]. Our case was secondary psoas abscess, which extended to the buttock through the eroded iliac bones bilaterally. The skeletal system, which is involved in 1%–10% of patients with tuberculosis, is the most common extrapulmonary site for tuberculous infection. Approximately half of skeletal system tuberculosis cases manifest as spinal diseases and 75% are accompanied by paraspinal abscess [2, 16]. A psoas abscess may form and may extend inferiorly as far as the groin and thigh under the psoas sheath along the the muscle course [3]. Subacute presentation along with nonspecific symptoms and signs makes the diagnosis of psoas abscess difficult [1]. The clinical signs and symptoms may include limping, a positive psoas sign, flexion deformity of the hip joint, fatigue, fever, night sweating, and weight loss [17]. The

chronic and insidious nature of tuberculous spondylitis causes late diagnosis of this disease.

The susceptibility of the psoas muscle as primary site can be attributed to its rich blood supply and proximity to overlying retroperitoneal lymphatic channels [18, 19]. Because the iliopsoas muscle inserts onto the lesser trochanter of femur, it is possible that the psoas abscess could extend to the medial side of the thigh under the inguinal canal [20] or to the hip joint [21, 22-24]. Extension up to the calf has also been reported [25]. Moreover, piriformis and gluteal abscesses have also been reported [12]. However, extension of the psoas abscess to the buttocks eroding through iliac wing is an extremely rare clinical manifestation.

The detection of the hidden psoas abscess requires high level of suspicion and failure to recognize and treat psoas abscess results in considerable morbidity [26]. The most common causative organism of the primary psoas abscess is *Staphylococcus aureus* whereas enteric organisms are responsible for the secondary type [7, 25, 15]. The spinal tuberculosis was the most common etiology half a century ago [26]. Fungal infection also should be excluded [25, 14, 27]. Other rare causes can be appendicitis, pancreatitis, pyelonephritis or Crohn's disease [18, 26]. The pathogenic organism could not be identified in our case but was presumed to be *Mycobacterium tuberculosis* based on clinical presentation, histological diagnosis and response to clinical treatment.

## CONCLUSION

In conclusion, in endemic regions patients with long standing psoas abscess can present as buttock abscesses, although bilateral presentation with perforation of iliac wings is very rare. Multiplanar imaging, especially MR imaging, is a useful diagnostic procedure in defining subtle vertebral disc or vertebral body lesions and in detecting unsuspected paravertebral soft-tissue extension. The abscess in our patient was large and extended to buttocks after eroding through iliac wings, thus demonstrating an additional route of extension of psoas abscess. The patient was treated successfully with open surgical drainage and anti-tubercular therapy.

## REFERENCES

1. Penado S, Espina B, Francisco Campo J. Abscess of the psoas muscle: description of a series of 23 cases. *Enferm Infecc Microbiol Clin* 2001; 19:257-60.
2. Levine MJ, Pedlow FX. Spinal infections. In: Garfin SR, Vaccaro AR, eds. *Orthopaedic Knowledge Update: Spine*. Rosemont, Ill: American Academy of Orthopedic Surgeons 1997; 257-271.
3. Dinc H, Ahmetoglu A, Baykal S, et al. Image-guided percutaneous drainage of tuberculous iliopsoas and spondylodiscitis abscesses: midterm results. *Radiology* 2002; 225:353-58.
4. Cronin CG, Lohan DG, Meehan CP, Delappe E, McLoughlin R, O'Sullivan GJ, McCarthy P. Anatomy, pathology, imaging and intervention of the iliopsoas muscle revisited. *Emerg Radiol* 2008; 15:295-310.
5. Mynter H. Acute psoitis. *Buffalo Med Surg J* 1881; 21:202-210.
6. Gruenwald I, Abrahamson J, Cohen O. Psoas abscess: case report and review of the literature. *J Urol* 1992; 147:1624-1626.
7. Ricci MA, Rose FB, Meyer KK. Pyogenic psoas abscess: worldwide variations in etiology. *World J Surg* 1986; 10:834-843.
8. Rawdha T, Leila S, Hadj Yahia Chiraz B, Leila A, Lilia C, Rafik Z. A rare cause of flank mass: tuberculous psoas abscess. *Intern Med* 2008; 47:985-9869.
9. Ebraheim NA, Rabenold JD, Patil V, Sanford CG. Psoas abscess: a diagnostic dilemma. *Am J Orthop* 2008; 37:E11-E13.
10. Sanal HT, Kocaoglu M, Schirlioglu A, Bulakbasi N. A rare cause of flank mass: psoas abscess due to extensive primary thoracolumbar tuberculous spondylodiskitis. *AJNR Am J Neuroradiol* 2006; 27:1735-1737.
11. Spedding RL, Walsh IK. Retroperitoneal abscess presenting with a buttock swelling and anaemia. *J Accid Emerg Med* 1999; 16:302-303.
12. Arai Y, Kawakami T, Soga H, Okada Y. Psoas abscess associated with iliac vein thrombosis and piriformis and gluteal abscesses. *Int J Urol* 1999; 6:257-259.
13. Kobayashi H, Sakurai Y, Shoji M, Nakamura Y, Saganuma M, Imazu H, et al. Psoas abscess and cellulitis of the right gluteal region resulting from carcinoma of the cecum. *J Gastroenterol* 2001; 36:623-628.
14. Yacoub WN, Sohn HJ, Chan S, Petrosyan M, Vermaire HM, Kelso RL, et al. Psoas abscess rarely requires surgical intervention. *Am J Surg* 2008; 196:223-227.
15. Taiwo B. Psoas abscess: a primer for the internist. *South Med J* 2001; 94:2-5.
16. Lindahl S, Nyman RS, Brismar J, et al. Imaging of tuberculosis. IV. Spinal manifestations in 63 patients. *Acta Radiol* 1996; 37:506-11.
17. Fam AG, Rubenstein J. Another look at spinal tuberculosis. *J Rheumatol* 1993; 20:1731-40.
18. Ramus NI, Shorey BA. Crohn's disease and psoas abscess. *Br Med J* 1975; 3:574-575.
19. Santaella RO, Fishman EK, Lipsett PA. Primary vs. secondary iliopsoas abscess. Presentation, microbiology, and treatment. *Arch Surg* 1995; 130:1309-1313.
20. Prassopoulos PK, Giannakopoulou CA, Apostolaki EG, Charoulakis NZ, Gourtsoyiannis NC. Primary ilio-psoas abscess extending to the thigh in a neonate: US, CT and MR findings. *Pediatr Radiol* 1998; 28:605-607.
21. Buttaro M, Gonzalez Della Valle A, Piccaluga F. Psoas abscess associated with infected total hip arthroplasty. *J Arthroplasty* 2002; 17:230-234.
22. Compain C, Michou L, Orcel P, Hannouche D, Richette P. Septic arthritis of the hip with psoas abscess caused by non-typhi *Salmonella* infection in an immunocompetent patient. *Joint Bone Spine* 2008; 75:67-69.
23. Kumagai K, Ushiyama T, Kawasaki T, Matsusue Y. Extension of lumbar spine infection into osteoarthritic

- hip through psoas abscess. *J Orthop Sci* 2005; 10:91–94.
24. Liu S, Leung H, Kadow C, Obrien JM. Septic arthritis of the hip complicating Salmonella psoas abscess. Case report. *Scand J Urol Nephrol* 1992; 26:305–306.
  25. Garner JP, Meiring PD, Ravi K, Gupta R. Psoas abscess-not as rare as we think? *Colorectal Dis* 2007; 9:269–274.
  26. Procaccino JA, Lavery IC, Fazio VW, Oakley JR. Psoas abscess: difficulties encountered. *Dis Colon Rectum* 1991; 34:784–789.
  27. Perros P, Sim DW, MacIntyre D. Psoas abscess due to retroperitoneal tuberculous lymphadenopathy. *Tubercle* 1988; 69:299–301.