

# Implantation Dermoid of the Distal Phalanx: A Missed Diagnosis

Vivek Sharma<sup>1</sup>, Ravinder Singh<sup>1</sup>, Amit Mittal<sup>2</sup>, Ashwani Ummat<sup>1</sup>, Arun Rathee<sup>1</sup>

<sup>1</sup>Department of Orthopedics, M.M. Institute of Medical Sciences and Research, Mullana, Haryana, India

<sup>2</sup>Department of Radiodiagnosis, M.M. Institute of Medical Sciences and Research, Mullana, Haryana, India

## ABSTRACT

Epidermoid inclusion cysts are benign lesions that occasionally occur in the distal phalanges of the fingers. A 30-year-old man presented with swollen and tender distal phalanx of the left middle finger. Radiographs showed an expansile lytic lesion in the tip of the distal phalanx with associated cortical erosions and minimal soft tissue component. CT scan revealed a well-defined lytic lesion with broken cortex at one place in the distal phalanx of the affected finger probably due to trauma. From clinical and radiological examination, a giant cell tumor, possibly aggravated by his injury, was suspected. The differential diagnosis included an inclusion cyst or a chronic infection. During operation, a cystic

lesion containing creamy material was obtained from within the bone which was sent for culture and sensitivity. After aspiration of the creamy material, a thick, yellow rind within the bone was completely removed and sent for histopathology. Bone graft was taken from the ipsilateral proximal ulna and suitably shaped to fill the cavity left after thorough curettage. Histopathology showed findings consistent with inclusion dermoid cyst. The patient recovered uneventfully, with normal functional digit and satisfactory radiographs. Epidermoid cysts of the bone are rare and mainly involve skull and phalanges. Diagnosis of such lesions is challenging and misdiagnosis may result in an unnecessary digital amputation.

**Keywords:** Epidermoid cyst; Implantation dermoid; Inclusion cyst; Distal phalanx

## INTRODUCTION

Epidermoid cysts of bone are rare and mainly involve the skull and terminal phalanges. Phalangeal involvement usually occurs in the distal phalanges of the fingers [1–4] although three cases of this lesion have been reported in the distal phalanx of great toe [5–7]. Epidermoid phalangeal cysts gradually enlarge and may or may not be accompanied by tenderness. These cysts are commonly regarded to be congenital, traumatic or iatrogenic in origin [1, 6, 8, 9]. A meticulous clinical and radiological examination is required but a final correct diagnosis is rarely made before corroborative operative findings and histopathological examination.

## CASE REPORT

A 30-year-old man, worker at railway yard, presented to our hospital outpatient department with swollen and tender left middle finger at the level of distal phalanx (Figure 1.1 and 1.2). He was being treated as fracture of distal phalanx, after suffering from an injury due to hammer, for

two months with no relief. The patient had previous injury to the same digit with avulsion of the nail 6 months ago. The nail had re-grown normally. The digit had gradually enlarged since the first injury but without any pain and tenderness. When he injured the same digit 4 months after the first injury he developed pain and tenderness. He also observed rapid increase in swelling after the second injury. The patient was being treated by a physician as fracture of the distal phalanx. The patient did not get relief in the pain for two months so he presented to us. General physical examination was normal and no other swelling or lymphadenopathy was found anywhere in the body. Radiographs showed an expansile lytic lesion at the tip of distal phalanx with associated cortical erosions and minimal soft tissue component (Figure 2.1 and 2.2). CT scan showed a well-defined lytic lesion with broken cortex at one place in the distal phalanx of the affected finger probably due to second injury (Figure 3.1 and 3.2).

Hematological investigations were normal. From clinical and radiological examination, a giant cell Tumor possibly aggravated by his injury was sus-

*Conflict of Interest: None declared*

*This article has been peer reviewed.*

*Article Submitted on: 6<sup>th</sup> May 2014*

*Article Accepted on: 20<sup>th</sup> July 2014*

*Funding Sources: None declared*

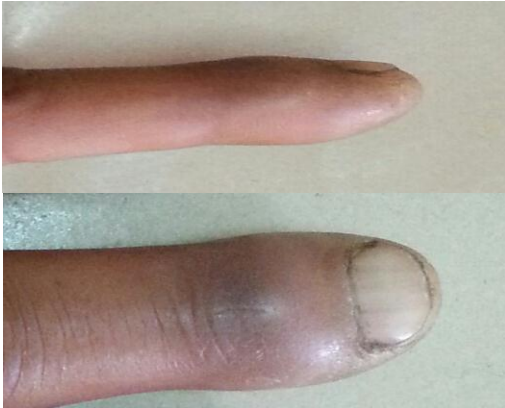*Correspondence to: Dr Vivek Sharma*

*Address: Department of Orthopedics, M.M. Institute of Medical Sciences and Research, Mullana, Haryana, India*

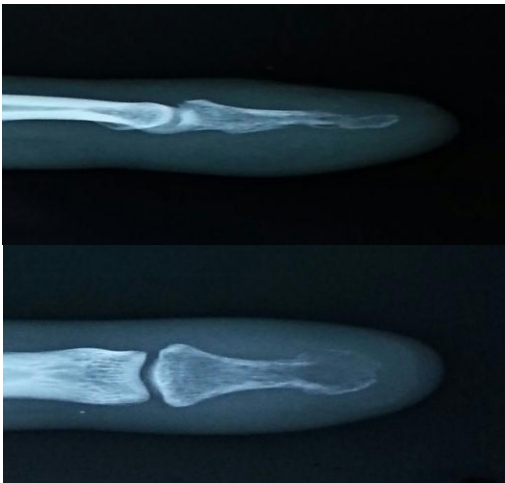*Email: [sharmavivek1979@yahoo.com](mailto:sharmavivek1979@yahoo.com)*

*Cite this Article: Sharma V, Singh R, Mittal A, Ummat A, Rathee A. Implantation dermoid of the distal phalanx: a missed diagnosis. J Pioneer Med Sci 2014; 4(4):180-183*

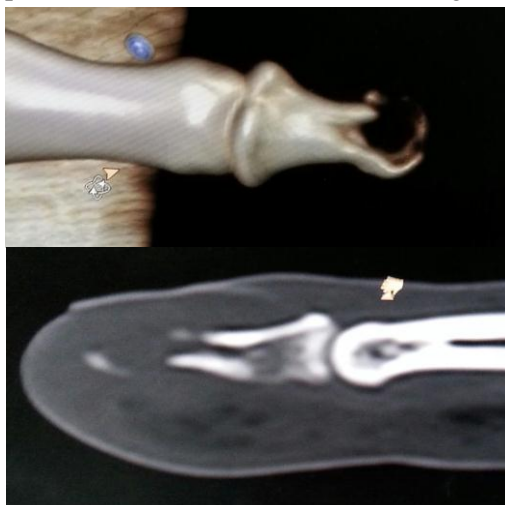
**Figure 1.1 and 1.2:** Affected left middle finger



**Figure 2.1 and 2.2:** Radiographs of distal phalanx of the affected left middle finger



**Figure 3.1 and 3.2:** CT Scan demonstrating lytic lesions with eroded cortex in distal phalanx of the affected left middle finger



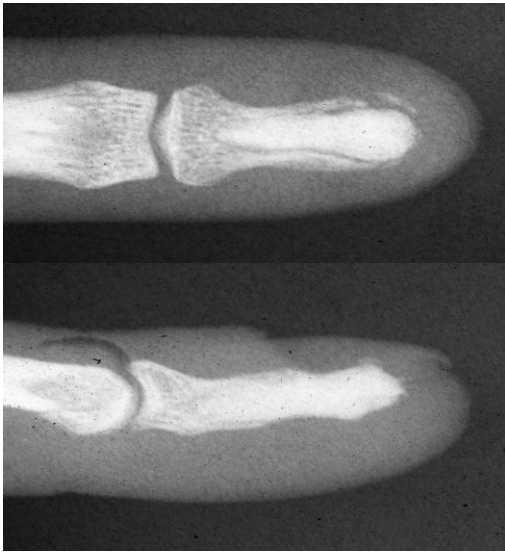
pected. The differential diagnosis included an inclusion cyst or chronic infection.

During the operation, after incision of the soft tissue over the phalanx, a creamy material was obtained from within the bone, which was sent for culture and sensitivity. After aspiration of the creamy material, a thick, yellow rind within the bone was completely removed, which was sent for histopathology. Bone graft was taken from the ipsilateral proximal ulna and suitably shaped to fill the cavity left after thorough curettage. Histopathology demonstrated that the wall of the cyst was composed of keratinizing stratified squamous epithelium with abundant keratin debris. There were no other skin appendages seen. Culture was negative after 48 hours of incubation. The patient recovered uneventfully, with normal functional digit and satisfactory radiographs (Figure 4.1 and 4.2).

## DISCUSSION

True epidermoid cysts result from the implantation of epidermal elements in the dermis and can result from trauma or a surgical procedure. Any skin puncture, laceration or incision has the potential to implant epidermal elements into the dermis and subcutaneous tissue, thereby producing a thick-walled cyst [12]. Epidermoid cysts are frequently seen in farmers, factory workers, carpenters and tailors who are subject to repeated minor traumas to the hand [13]. Human papilloma virus infection, ultraviolet exposure and eccrine duct obstruction are also suggested to be the additional risk factors in the development of palmoplantar epidermoid cysts [14-16]. The epidermoid inclusion cysts of the hands usually present as asymptomatic, slowly enlarging, painless, superficial and localized swellings over the volar aspect of the hand, especially the distal portion of the digits. Occasional cases of epidermoid inclusion cyst arising from deeper structures like tendon and phalangeal bones have also been reported [3, 17, 18]. The epidermoid cysts are usually benign lesions; however, rare cases of malignancies have also been reported [19-21]. Epidermoid cysts are often site-specific. The history of associated trauma and basic clinical examination may be helpful in the diagnosis. Radiological investigations usually do not lead to definitive diagnosis. Computed tomography and magnetic resonance imaging [22] are helpful in delineating the anatomy of the soft tissue tumors, although seldom necessary to guide the treatment. Differentiation of epidermoid cysts from other

**Figure 4.1 and 4.2:** Radiograph of the affected digit at six months



radiolucent digital lesions remains challenging [24]. Epidermoid inclusion cysts of the hand need to be differentiated from ganglions, giant cell tumors of bones and tendon sheath, lipomas and bony and arthropathic swellings [12, 25]. Fine needle aspiration cytology (FNAC) may have a role in making cytological diagnosis if enough keratin or sebaceous material is obtained. Histological examination helps in the definitive diagnosis as it is important to differentiate this benign lesion from other benign and malignant lesions of the bone [23].

Because most of the hand epidermoid cysts are benign and asymptomatic, surgical intervention is not warranted. The surgical treatment is needed for symptomatic cysts causing interference with hand function. The treatment requires careful complete excision, which can easily be accomplished with regional anesthesia under pneumatic tourniquet [26]. Removal of the entire cyst wall is necessary to avoid the recurrence [27]. Although it has been reported that an unduly large number of phalangeal cysts have been treated by amputation, the judicious planning of treatment can prevent this scenario. In our case, the lesion was likely caused by initial trauma and was asymptomatic initially. It became symptomatic due to second trauma.

## CONCLUSION

Epidermoid cysts of the bone are rare and mainly involve the skull and phalanges. Diagnosis of such lesions can be easily missed if proper clinical and diagnostic skills are not applied. It is

important to perform thorough investigations and include this lesion in the differential diagnosis to avoid unnecessary treatment.

## REFERENCES

1. Carroll RE. Epidermoid (epithelial) cyst of the hand skeleton. *Am J Surg* 1953; 85:327–334.
2. Zadek L, Cohen HG. Epidermoid cyst of the terminal phalanx of the finger. *Am J Surg* 1953; 85:771–774.
3. Hinrichs RA. Epidermoid cyst of the terminal phalanx of the hand: case report and brief review. *JAMA* 1965; 194:1253–1254.
4. Hensley CD. Epidermoid cyst of the distal phalanx occurring in an eight year old child. *J Bone Joint Surg* 1966; 48:946–948.
5. Roth SI. Squamous cysts involving the skull and distal phalanges. *J Bone Joint Surg* 1964; 46:1442–1450.
6. Schajowicz F, Aiello CJ, Stullitel I. Cystic and pseudocystic lesions of the terminal phalanx with special reference to epidermoid cysts. *Clin Orthop Relat Res* 1970; 68:84–92.
7. Tamburrelli F. A case of epidermoid cysts of the distal phalanx of the big toe [in Italian]. *Arch Putti Chir Organi Mov* 1984; 34:417–422.
8. Kirsch WM, Hodges FJ 3rd. An intramedullary epidermal inclusion cyst of the thoracic cord associated with a previously repaired meningocele: case report. *J Neurosurg* 1966; 24:1018–1020.
9. Kalisher L. Epidermoid inclusion cysts of the phalanx, radiological and clinical correlation. *Rev Interam Radiol* 1977; 2:47–48.
10. Handa U, Kumar S, Mohan H. Aspiration cytology of epidermoid cyst of terminal phalanx. *Diagn Cytopathol* 2002; 26:266–267.
11. Ribeiro EB. Epidermoid cyst of the terminal phalanx of the hand. *Int Surg* 1967; 47:336–339.
12. Lucas GL. Epidermoid inclusion cysts of the hand. *J South Orthop Assoc* 1999; 8:188–92.
13. McFarland GB. Soft tissue tumors. In: Green DP, editor. *Operative hand surgery*. 2nd ed. New York: Churchill Livingstone; 1988.
14. Egawa K, Honda Y, Inaba Y, Ono T, De Villiers EM. Detection of human papillomaviruses and eccrine ducts in palmoplantar epidermoid cysts. *Br J Dermatol* 1995; 132:533–42.
15. Egawa K, Kitasato H, Ono T. A palmar epidermoid cyst, showing histological features suggestive of eccrine duct origin, developing after a bee-string. *Br J Dermatol* 2000; 143:469–70.
16. Park HS, Kim WS, Lee JH, Yang JM, Lee ES, Jang KT, et al. Association of human papillomavirus infection with palmoplantar epidermal cysts in Korean patients. *Acta Derm Venereol* 2005; 85:404–8.
17. O'Hara JJ, Stone JH. An intratendinous epidermoid cyst after trauma. *J Hand Surg Am* 1990; 15:477–9.
18. Hamad AT, Kumar A, Anand Kumar C. Intraosseous epidermoid cyst of the finger phalanx: A case report. *J Orthop Surg (Hong Kong)* 2006; 14:340–2.
19. Bauer B. Carcinoma arising in a sebaceous cyst. *IMJ Ill Med J* 1979; 156:174–6.  
Lopez-Rios F, Rodriguez-Peralto JL, Castano E, Benito A. Squamous cell carcinoma arising in a cutaneous epidermal cyst: case report and literature review. *Am J Dermatopathol* 1999; 21:174–7.
21. Cameron DS, Hilsinger RL Jr. Squamous cell carcinoma in an epidermal inclusion cyst: case report. *Otolaryngol Head Neck Surg* 2003; 129:141–3.
22. Horcajadas AB, Lafuente JL, de la Cruz Burgos R,

- Muñiz SH, Roca SA, Ortega SG, et al. Ultrasound and MR findings in tumor and tumor-like lesions of the fingers. *Eur Radiol* 2003; 13:672–85.
23. Kalsotra N, Singh M, Sharma S, Singh D. Digital epidermoid cyst of the finger phalanx: a case report. *Orthopedic Research and Reviews* 2010; 2:71-73.
  24. David E. Ruchelsman, Daniel K. Laino, Kimberlly S. Chhor, German C. Steiner, Samuel Kenan. Digital intraosseous epidermoid inclusion cyst of the distal phalanx: A case report. *J Hand and Microsurg* 2010; 2:24-27.
  25. Goebel SX, Rasi LM, Stern PJ. Multiple epidermal inclusion cysts in a patient with rheumatoid arthritis: A case report. *J Hand Surg Am* 2000; 25:768–71.
  26. Ariyan S. Benign and Malignant Soft Tissue Tumors of the hand. In: McCarthy JG, editor. *Plastic Surgery*. United States: WB Saunders Company; 1990.
  27. Lincoski CJ, Bush DC, Millon SJ. Epidermoid cysts in the hand. *J Hand Surg Eur* 2009; 34:792–6.