

Peripheral Ossifying Fibroma: A Case Report

Vikas Singh¹, D.J. Bhaskar², Swapnil S. Bumb¹, Mallika Kishore³, Safalya S. Kadtane¹

¹Senior Lecturer, Department of Public Health Dentistry, Teerthanker Mahaveer Dental College and Research Center, Moradabad, U.P., India

²Professor & H.O.D., Department of Public Health Dentistry, Teerthanker Mahaveer Dental College and Research Center, Moradabad, U.P., India

³MDS, Private Practitioner, Department of Oral Medicine and Radiology, Institute of Dental Sciences, Bareilly, U.P., India

ABSTRACT

Peripheral ossifying fibroma is a reactive gingival overgrowth occurring frequently in the anterior maxilla in teenagers and young adults. It is a non-neoplastic enlargement of gingiva. Due to its clinical and histopathological similarities, some POFs are believed to develop initially as a pyogenic granuloma that undergoes fibrous maturation and subsequent calcification. The peak incidence is found most frequently in teenagers and young adults. Trauma or local irritants such as dental plaque, calculus, micro-organisms, masticatory forces, ill-fitting dentures and poor quality restorations have been

implicated in the etiology of peripheral ossifying fibroma. Here we present a case report of peripheral ossifying fibroma in a 35-year-old female. This case report comprises the growth that occurred in the maxillary anterior region with displacement of anterior teeth, its management and literature review. The lesion was asymptomatic, sessile, firm and pinkish-red in color. Excision biopsy of the lesion revealed histopathological features consistent with peripheral ossifying fibroma. Therefore, careful clinical examination and histopathological findings should be correlated to conclude the final diagnosis.

Keywords: Peripheral ossifying fibroma; Micro-organisms; Masticatory; Calculus

INTRODUCTION

Peripheral ossifying fibroma (POF) accounts for 3.1% of all oral tumors and for 9.6% of all gingival lesions [1, 2]. Synonyms of POF are peripheral cementifying fibroma, calcifying or ossifying fibroid epulis, and peripheral fibroma with calcification [3]. In 1872, Menzel first described the ossifying fibroma, but only in 1927, did Montgomery assign its terminology [4]. The POF may appear ulcerated and erythematous or exhibit a color similar to the surrounding gingiva. It may be pedunculated or sessile and usually does not blanch upon palpation [5]. The POF may occur at any age, but exhibits a peak incidence between the second and third decades. The average age is around 28 years, with females being affected more often than males. Approximately 60% of POFs occur in the maxilla, often in the anterior than the posterior area, with 55%–60% presenting in the incisor-cuspid region. The pathogenesis of this tumor is uncertain; however, the pluripotent cells of the periodontal ligament have the apparent ability to transform or metaplastically change

into osteoblasts, cementoblasts or fibroblasts, in response to irritants such as calculus, bacterial plaque, orthodontic appliances, ill-adapted crowns and irregular restorations and are therefore, capable of producing a unique inflammatory hyperplasia, the peripheral ossifying fibroma [6-8]. Incidences of recurrence have been put at 16–20% [9]. The purpose of this article is to present a case of POF, briefly review the current literature on this condition and emphasize the importance of discussion of a reasonable differential diagnosis with the patient. As the clinical spectrum of this entity has resemblance to other common gingival masses, a thorough diagnostic work-up is necessary to rule out other common benign gingival lesions.

CASE REPORT

A 35-year-old female patient presented to the Department of Public Health Dentistry with a chief complaint of swelling in the upper front tooth region for 2 years. Initially, the swelling was small but it gradually increased in size. Swelling was not associated with pain but

Conflict of Interest: None declared

This article has been peer reviewed.

Article Submitted on: 12th March 2014

Article Accepted on: 8th July 2014

Funding Sources: None declared

Correspondence to: Dr Vikas Singh

Address: Department of Public Health Dentistry, Teerthanker Mahaveer Dental College and Research Center, Moradabad, U.P., India

Email: drvikas7@gmail.com

Cite this Article: Singh V, Bhaskar DJ, Bumb SS, Kishore M, Kadtane SS. Peripheral ossifying fibroma: a case report. *J Pioneer Med Sci* 2014; 4(4):177-179

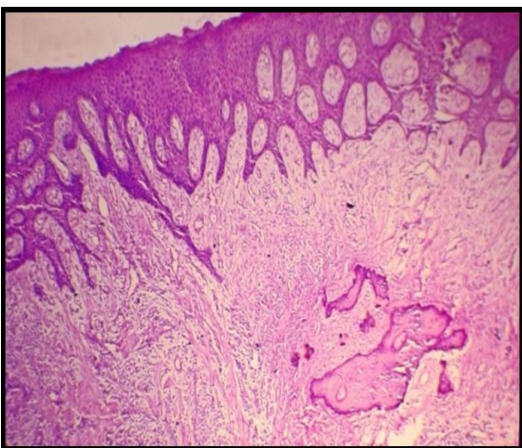
Figure 1: Clinical presentation showing well-defined gingival growth with respect to lateral incisor and canine

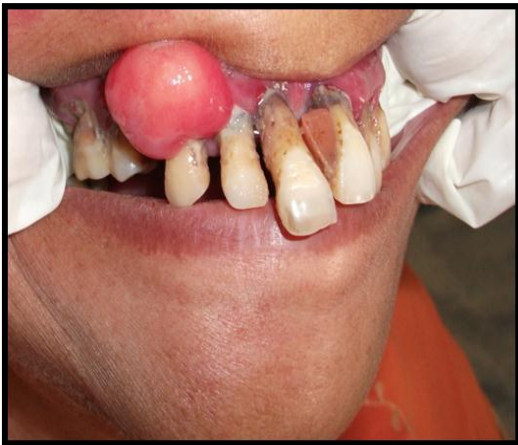

Figure 2: Orthopantomogram of the patient showing generalized horizontal bone loss

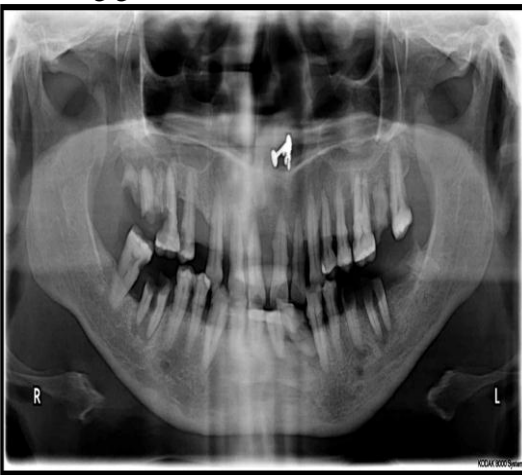

Figure 3: Histopathological picture showing fibroblastic stroma with varying cellularity



patient reported bleeding during brushing teeth. Her past dental and medical history was non contributory. On intraoral examination, generalized stains and calculus, gingival recession was present, 14 and 37 were clinically missing with grossly carious 15, 16 and root stumps were present in relation to 17, 18, 46, 35, 36, 38 and grade II mobility was present with respect to 11, 12, 13, 21. A solitary, well-defined gingival growth was present on the maxillary anterior teeth region with relation to right maxillary lateral incisor and canine. It was roughly oval in shape and measured about 3 x 2 cm in its greatest dimensions. It extended from the distal aspect of 12 to medial aspect of 15. The overlying mucosa appeared pale pink to reddish pink in color with normal surrounding mucosa (Figure 1). On palpation, all observations were confirmed. The growth was firm in consistency, non-tender and was not associated with any discharge. On the basis of the history and clinical features, a provisional diagnosis of POF with respect to 12, 13, 15 was made. Clinically, the differential diagnosis of pyogenic granuloma and peripheral giant cell granuloma were considered. Patient underwent orthopantomogram and complete hemogram followed by excisional biopsy of the lesion. The panoramic view showed generalized horizontal bone loss along with periapical radiolucency with respect to 46, 35, 36 (Figure 2). The excisional biopsy was performed under local anesthesia. Excised specimen section revealed fibroblastic stroma with varying cellularity. Within the fibrous stroma, mineralized tissue masses that corresponded to osteoid or cementoid material accompanied by dystrophic calcifications were noted (Figure 3). Based on the patient's history, clinical and histological findings, the final diagnosis of POF with respect to 12, 13, 15 was given.

DISCUSSION

Intraoral ossifying fibromas have been described in literature since the late 1940s. POF are sessile or pedunculated, usually ulcerated and erythematous or exhibit a color similar to the surrounding gingiva [10]. POF occur mostly in craniofacial bones and are categorized into two types; central and peripheral. The central type of POF arise from the endosteum or the periodontal ligament (PDL) adjacent to the root apex and expand from the medullary cavity of the bone while the peripheral type occur on the soft tissues overlying the alveolar process [5].

The main etiological factors of POF are trauma

and chronic irritation, particularly from the subgingival plaque and calculus [12]. It is widely considered that this lesion originates from the cells of periodontal ligament [11]. It is most commonly seen in second to third decade of life with female predilection of 5:1 ratio [13, 14]. Only 0.5% cases are reported in the older age group. Sixty percent of POFs occur in the maxilla and they are found more often in the anterior region, with 55-60% presenting in the incisor-cuspid region [15]. Radiographically, migration of teeth with interdental bone destruction has been reported in some cases but in a vast majority of cases there is no apparent underlying bone involvement. On rare occasions, there appears to be superficial erosion of bone [16]. Clinical differential diagnosis for gingival growths includes fibroma, peripheral giant cell granuloma, pyogenic granuloma, peripheral odontogenic fibroma and peripheral ossifying fibroma. Histologically, POF should be differentiated from peripheral odontogenic fibroma. Unlike the POF, the peripheral odontogenic fibroma is a real tumorous condition and has an odontogenic epithelium and dysplastic dentine. It has been observed that POF in some cases may initially develop as a pyogenic granuloma that undergoes subsequent fibrous maturation and calcification [17]. The lesions should be surgically excised and submitted for microscopic examination for confirmation of the diagnosis. Treatment of POF consists of elimination of etiological factors, scaling of adjacent teeth and total aggressive surgical excision along with involved periodontal ligament and periosteum to minimize the possibility of recurrence [18]. Follow-up is essential because of high recurrence rates. Incidence of recurrence have been estimated at 16–20%. The reasons for recurrence include incomplete removal of the lesion, failure to eliminate local irritants and difficult surgical access during surgical manipulation due to intricate location of POF being present usually at interdental areas [6].

CONCLUSION

A peripheral cement-ossifying fibroma is a slowly progressing lesion, the growth of which is generally limited. POF being one of the commonest solitary swellings in the oral cavity is often clinically diagnosed as pyogenic granuloma. Radiological and histopathological examination is required for confirmation of the diagnosis.

REFERENCES

1. Kenney JN, Kaugars GE, Abbey LM. Comparison between the peripheral ossifying fibroma and peripheral odontogenic fibroma. *J Oral Maxillofac Surg* 1989; 47:378–82.
2. Walters JD, Will JK, Hatfield RD, Cacchillo DA, Raabe DA. Excision and repair of the peripheral ossifying fibroma: A report of 3 cases. *J Periodontol* 2001; 72:939–44.
3. Eversole LR, Rovin S. Reactive lesions of the gingiva. *J Oral Pathol* 1972; 1:30–8.
4. Eversole LR, Sabers WR, Rovein S. Fibromy dysplasia: A nosology problem in the diagnosis of fibro-osseous lesion of the jaw. *J Oral Pathol* 1972; 1:189–220.
5. Walters JD, Will JK, Hatfield RD, Cacchillo DA, Raabe DA. Excision and repair of the peripheral ossifying fibroma: A report of 3 cases. *J Periodontol* 2001; 72:939–944.
6. Bhasin M, Bhasin V, Bhasin A. Peripheral ossifying fibroma. *Case Rep Dent* 2013; 2013:497234.
7. Kumar SK, Ram S, Jorgensen MG, Shuler CF, Sedghizadeh PP. Multicentric peripheral ossifying fibroma. *J Oral Sci* 2006; 48:239–43.
8. Mesquita RA, Orsini SC, Sousa M, de Araújo NS. Proliferative activity in peripheral ossifying fibroma and ossifying fibroma. *J Oral Pathol Med* 1998; 27:64–7.
9. Carrera Grañó I, BeriniAytés L, Escoda CG. Peripheral ossifying fibroma: Report of a case and review of the literature. *Med Oral* 2001; 6:135–41.
10. Shetty DC, Urs AB, Ahuja P, Sahu A, Manchanda A, Sirohi Y. Mineralized components and their interpretation in the histogenesis of peripheral ossifying fibroma. *Indian J Dent Res* 2011; 22:56–61.
11. Das UM, Azher U. Peripheral ossifying fibroma. *J Indian Pedodprevent Dent* 2009; 1:49–51.
12. Cuisa ZE, Brannon RB. Peripheral ossifying fibroma: A clinical evaluation of 134 pediatric cases. *Pediatr Dent* 2001; 23:245–8.
13. Eversole LR, Leider AS, Nelson K. Ossifying fibroma: a clinicopathologic study of sixty-four cases. *Oral Surg Oral Med Oral Pathol* 1985; 60:505–11.
14. Jung SL, Choi KH, Park YH, Song HC, Kwon MS. Cemento-ossifying fibroma presenting as a mass of the parapharyngeal and masticator space. *AJNR Am J Neuroradiol* 1999; 20:1744–6.
15. Farquhar T, Maclellan J, Dyment H, Anderson RD. Peripheral ossifying fibroma: a case report. *J Can Dent Assoc* 2008; 74:809–812.
16. Poon CK, Kwan PC, Chao SY. Giant peripheral ossifying fibroma of the maxilla: report of a case. *J Oral Maxillofac Surg* 1995; 53:695–698.
17. Prasad S, Reddy SB, Patil SR, Kalburgi NB, Puranik RS. Peripheral ossifying fibroma and pyogenic granuloma. Are they interrelated? *N Y State Dent J* 2008; 74:50–2.
18. Mishra MB, Bhishen KA, Mishra S. Peripheral ossifying fibroma. *J Oral Maxillofac Pathol* 2011; 15:65–68.