

Sphenopalatine Pseudoaneurysm Post-Endoscopic Turbinoplasty

Mohamad Azizul Fitri Bin Khalid¹, Norhafiza Mat Lazim², Norzi Bt Gazali³

¹Senior Medical Officer, ORL-HNS Department, School of Medical Sciences, Universiti Sains Malaysia, Kelantan, Malaysia

²Lecturer, ORL-HNS Department, School of Medical Sciences, Universiti Sains Malaysia, Kelantan, Malaysia

³Physician, ORL-HNS Department, Hospital Sultanah Bahiyah, Kedah, Malaysia

ABSTRACT

Pseudoaneurysm is a rare occurrence mainly affecting vessels in the head and neck region, especially the superficial temporal artery, which is a branch of the internal maxillary artery. Most of the time, these aneurysms are secondary to trauma to the face, surgical procedures, or infections. The best imaging modality is angiography;

however, alternative less-invasive imaging such as CT angiogram is also helpful in establishing the diagnosis and treatment. Most patients are asymptomatic; however, few patients will need surgical intervention and/or embolization to prevent bleeding as a complication.

Keywords: Pseudoaneurysm; Internal Maxillary Artery; Embolization; Endoscopic Turbinoplasty

INTRODUCTION

Pseudoaneurysm is a rare occurrence and usually results from blunt trauma to the vessel wall with resultant laceration. This leads to extravasation of blood to the surrounding tissue which is followed by a tamponade and clot formation. Incidence of pseudoaneurysm of extracranial carotid artery is rare because the trauma usually results in total transection rather than partial laceration of the vessel. Superficial temporal artery, internal maxillary artery and distal facial artery are commonly affected arteries because of their location, which are near the mandible and zygomatic bone [1]. Most aneurysms (~85%) are found extracranially in the head and neck region and the artery that is commonly involved is the superficial temporal artery followed by internal maxillary artery and facial artery [2]. Internal maxillary artery (IMA) pseudoaneurysm is rare and most lesions are associated with fracture of the neck of the mandible [3, 4]. Here we present a case of a pseudoaneurysm of the right sphenopalatine artery after endoscopic turbinoplasty. To the authors' knowledge, this is a rarely reported incident.

CASE REPORT

A 33-year-old male presented to the otorhinolaryngology clinic in Hospital Sultanah Bahiyah with complaints of occasional nasal blockage associated with rhinorrhea and

difficulty in sleeping. His medical history was significant for a motor vehicle accident one year ago in which he sustained facial trauma with bilateral Le Fort II fracture and left Le Fort III fracture and nasal bone fractures (Figure 1). He underwent facial reconstructive surgery one month following the accident.

Six months later, he developed left epiphora and was referred to the specialist otorhinolaryngology clinic for left endoscopic dacrocystorhinostomy (EDCR). A CT scan of paranasal sinuses showed left nasolacrimal duct obstruction secondary to a fractured lacrimal fossa and nasolacrimal canal (Figure 2 and Figure 3). The patient subsequently underwent left EDCR and recovered without any incident. Immediately postoperatively, there were no symptoms of nasal blockage, epistaxis or recurrent epiphora. The nasal blockage symptoms developed about four months post EDCR. Routine nasoendoscopic examination performed at the clinic during the presentation showed bilateral inferior turbinates hypertrophy with small septal spur on the left side of the septum. He was treated conservatively for two months with a topical intranasal steroid, oral antihistamine, and lifestyle modification, but his symptoms persisted. He was then advised for endoscopic bilateral turbinoplasty in view of persistence of his symptoms.

Bilateral turbinoplasty under general anesthesia was carried out as an elective procedure. Turbinoplasty was carried out using cold instruments and part of inferior turbinate mucosa

Conflict of Interest:
None declared

This article has been peer reviewed.

Article Submitted on: 15th August 2012

Article Accepted on: 3rd February 2013

Funding Sources: None declared

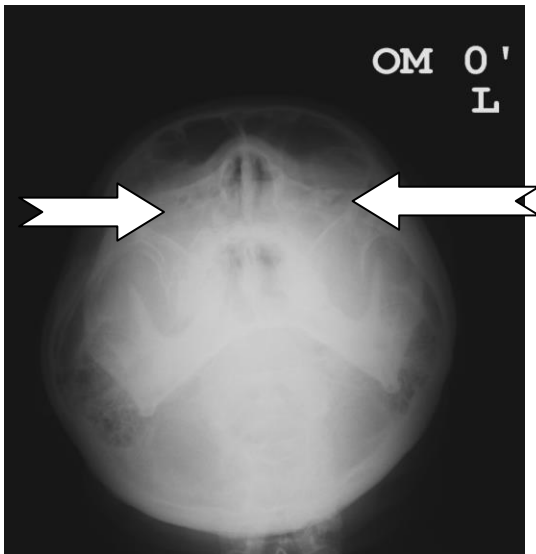
Correspondence to: Dr. Norhafiza Mat Lazim

Address: ORL-HNS Department, School of Medical Sciences, Universiti Sains Malaysia, Kelantan, Malaysia

E-mail:
norhafiza@kck.usm.my

Cite this Article: Khalid MAFB, Lazim NM, Gazali NB. Sphenopalatine pseudoaneurysm postendoscopic turbinoplasty. *J Pak Med Stud*; 3(2):72-75

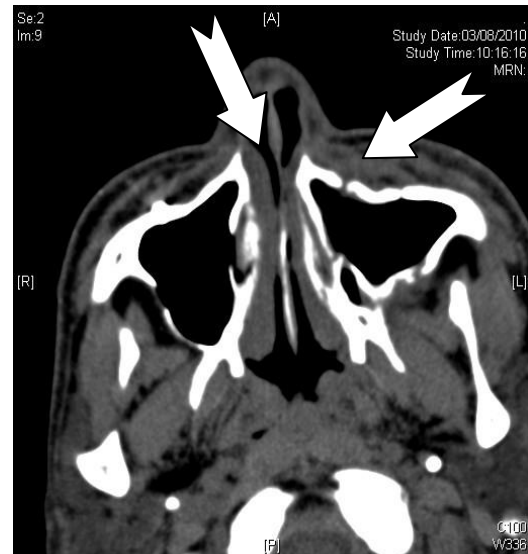
Figure 1: Occipital-mental view of skull X-ray at zero degree plain radiograph showing site of Le Fort fracture



and small part of bony inferior turbinates were removed. Both nostrils were packed with tampon nasal packs to secure homeostasis. Immediately post operatively, the patient developed an episode of excessive epistaxis from his right nasal cavity. Examination under anesthesia revealed an active bleeding site in the right nasopharynx area just behind the right inferior turbinate. Hemostasis was secured via diathermy and nasal packing was repeated. Four units of fresh frozen plasma were transfused intraoperatively. Patient suffered from blood loss and his hemoglobin dropped from 13.4 g/dL preoperatively to 9.7g/dL. However, the patient did not require packed cell transfusion after the event as he appeared hemodynamically stable. At postoperative day four, the nasal packing was removed and patient was discharged. He presented again the following day with symptom of repeated episode of massive epistaxis at home. In the emergency unit, nasal packing was again repeated to secure the bleeding and patient was admitted. During the admission, he developed sudden episode of hypertension with blood pressure ranging from 130/90-150/100 mmHg. He was started on oral amlodipine 10 mg daily to stabilize his blood pressure.

A CT angiogram was arranged the next day and the findings were suspicious of right sphenopalatine artery pseudoaneurysm (Figure 3 and Figure 4). The CT angiogram showed dilated vessel measuring 0.4 cm in diameter and 1.5 cm in length seen at the posteroinferior part of right

Figure 2: Axial view of CT scan of paranasal sinuses showing old fractures of left maxilla and the state of intranasal cavity pre EDCR

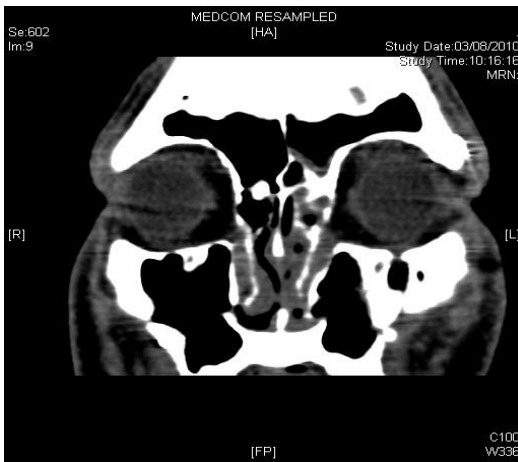


nasal cavity with the feeding vessel from the right internal maxillary artery [Figure 5]. Multiple old fractures of the facial bone were also demonstrated. He later underwent embolization at a referral center by an interventional radiologist. At present, patient is doing well at three monthly follow-ups at our rhinology clinic. During his last follow-up, a routine zero degree rigid nasoendoscopy showed synechiae formation in the right nasal cavity between the posterior part of right inferior turbinates and the septum. However, patient was asymptomatic and not keen for a synechiae release.

DISCUSSION

Aneurysm consists of two types, a true aneurysm and a pseudoaneurysm. In true aneurysm, the aneurysmal wall contains all the vessel wall layers. Pseudoaneurysm is formed when the wall of an artery is partially transected causing blood to fill in the cavities with subsequent pseudocapsule formation around the vessel. This pseudocapsule surrounds the hematoma and is fibrous in nature. Cavitations that occur inside a hematoma form the pseudoaneurysm [2, 4]. Pseudoaneurysms involving branches of external carotid artery are rare and are usually caused by penetrating or blunt trauma, partially transecting the vessel wall [1]. Rogers et al reported two cases of Le Fort III fractures and Le Fort I osteotomy with subsequent development of

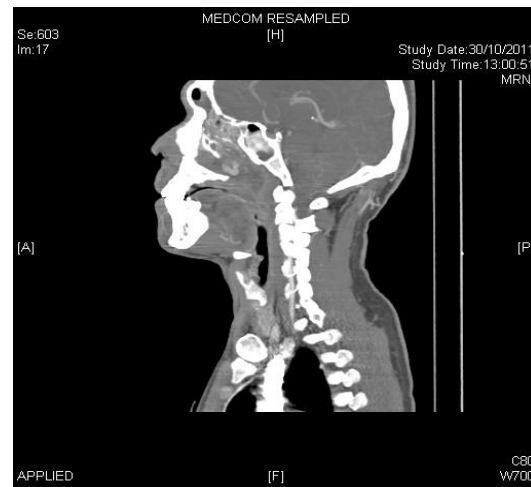
Figure 3: Coronal view of CT scan of paranasal sinuses showing the narrowing of left nasolacrimal canal complicated by the Le Fort fracture



pseudoaneurysm in internal maxillary artery; patients presented with epistaxis weeks after surgery [5]. Gerbino et al reported a case of IMA pseudoaneurysm in a patient six months after Le Fort I fracture [4]. Facial fractures are also found to have late vascular complications and warrant frequent follow-ups [6, 7]. In our case, even though the cause of epistaxis was iatrogenic in nature, we believe that the initial facial trauma was the likely cause of pseudoaneurysm. Another explanation is the manipulation of facial bones during facial reconstruction surgery which might injure the right sphenopalatine artery causing pseudoaneurysm formation.

Imaging must be done to investigate the cause of bleeding especially in a postoperative patient. According to Procopio et al, while investigating the cause of major bleeding after Le Fort osteotomy, angiography is the diagnostic examination of choice [8]. They also described plain CT without contrast to be useful in defining the bone anatomical change, side of pathology and vessel relationship. A CT scan with contrast will be able to give detailed information on the pathological anatomy [8]. In this case, after the second episode of bleeding, we decided to proceed with CT angiogram as the history of trauma and previous operation were significant enough to suggest a bleeding pseudoaneurysm. Some authors reported that although the diagnosis of IMA pseudoaneurysm is best obtained with angiography, contrast enhanced CT is useful enough to establish the site of pseudoaneurysm if it is more than 1 cm in size [9]. This will help to guide the interventional

Figure 4: Sagittal view of face CT scan angiogram showing aneurysm at posterior part of the nasal cavity

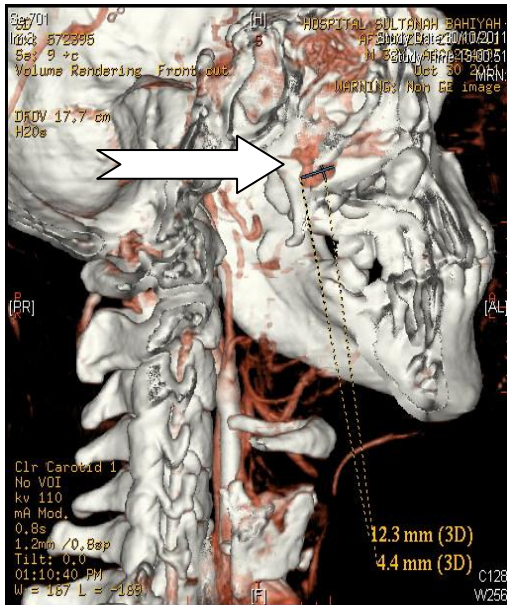


radiologist or vascular surgeon to selectively embolize the affected vessel.

The objective in treating pseudoaneurysm is to obtain proximal and distal control before the aneurysm is excised [4]. However, currently the pseudoaneurysm is better treated by endovascular embolization using a catheter, which is most of the time performed by an interventional radiologist [2]. Few agents can be used to embolize the involved vessels such as polyvinyl alcohol foam, gel foam, steel coils, methyl methacrylate and silicone spheres [5]. Embolization does require an experienced interventional radiologist. It may also cause serious neurological complications such as ophthalmoplegia, facial paralysis and hemiplegia at rates of 0–8% [10]. Rodesch et al encountered complications of 0.4% and 1% permanent and transient complications secondary to chemoembolization for epistaxis. About 0.4% of his cases developed nasal septum necrosis [11]. Ntomouchtsis et al reported a complicated and unfortunate case of right IMA post-embolization for epistaxis of a patient that developed left-sided hemiparesis and right-sided facial nerve paresis, followed by ulceration and necrosis of the soft palate, nasal septum, and right nasal ala [12]. This shows that although complications of selective embolizations are rare, there is potential for extensive and debilitating complications. In our case, there was no incidence of complications or rebleeding after the embolization and initial embolization was successful.

In summary, we present a case of pseudoaneurysm which was diagnosed

Figure 5: A reconstructed image of face CT angiogram showing the pseudoaneurysm location in 3-dimensions



postoperatively and the etiology of pseudoaneurysm could have been an operative complication or previous history of facial fracture. Pseudoaneurysm was diagnosed with CT angiography and was treated with chemoembolization of the involved artery with good results.

REFERENCES

1. Dediol E, Manojlovic S, Biocic J, Franceski D, Ivanac G. Facial artery pseudoaneurysm without evidence of trauma. *Int J Oral Maxillofac Surg* 2011; 40:988-990.
2. Aiyer RG, Mehta S, Kumar G, Gupta D. Pseudoaneurysm of the facial artery. *Indian J Otolaryngol Head Neck Surg* 2002; 54:221-222.
3. Pinjala RK, Joshi S, Rammurti S. Traumatic pseudoaneurysm of the internal maxillary artery. *EJVES Extra* 2007; 14:54-55.
4. Gerbino G, Roccia F, Grosso M, Regge D. Pseudoaneurysm of the internal maxillary artery and Frey's syndrome after blunt facial trauma. *J Oral Maxillofacial Surg* 1997; 55:1485-1490.
5. Rogers SN, Patel M, Beirne JC, Nixon TE. Traumatic aneurysm of the maxillary artery: the role of interventional radiology. A report of two cases. *Int J Oral Maxillofac Surg* 1995; 24:336-339.
6. Nardis AC, Boraks G, Torres AM, Gaigier ET, da Silva AR. Uncommon complication of facial fractures. *Int J Oral Maxillofac Surg* 2011; 40:440-442.
7. Newman F, Cillo JE. Late vascular complication associated with panfacial fractures. *J Oral Maxillofac Surg* 2008; 66:2374-2377.
8. Procopio O, Fussetti S, Liessi G, Ferronato G. False aneurysm of the sphenopalatine artery after a Le Fort I osteotomy: report of 2 cases. *J Oral Maxillofac Surg* 2003; 61:520-524.
9. Lu C, Teng MM, Chiang F, Chang C. Role of CT and endovascular embolization in managing pseudoaneurysm of the internal maxillary artery. *J Chin Med Assoc* 2006; 69:310-316.
10. Kamani T, Shaw S, Ali A, Manjaly G, Jeffree M. Sphenopalatine-sphenopalatine anastomosis: a unique cause of intractable epistaxis, safely treated with microcatheter embolization: a case report. *J Med Case Reports* 2007; 1:125-127.
11. Rodesch G, Alvarez H, Lasjaunias P. Embolization of Epistaxis. In Golzarian J, Sun S, Sharafuddin M (Eds.), *Vascular Embolotherapy* Berlin. Springer Berlin Heidelberg 2006; 257-270.
12. Ntomouchtsis A, Venetis G, Zouloumis L, Lazaridis N. Ischemic necrosis of nose and palate after embolization for epistaxis. A case report. *Oral Maxillofac Surg* 2010; 14:123-127.