

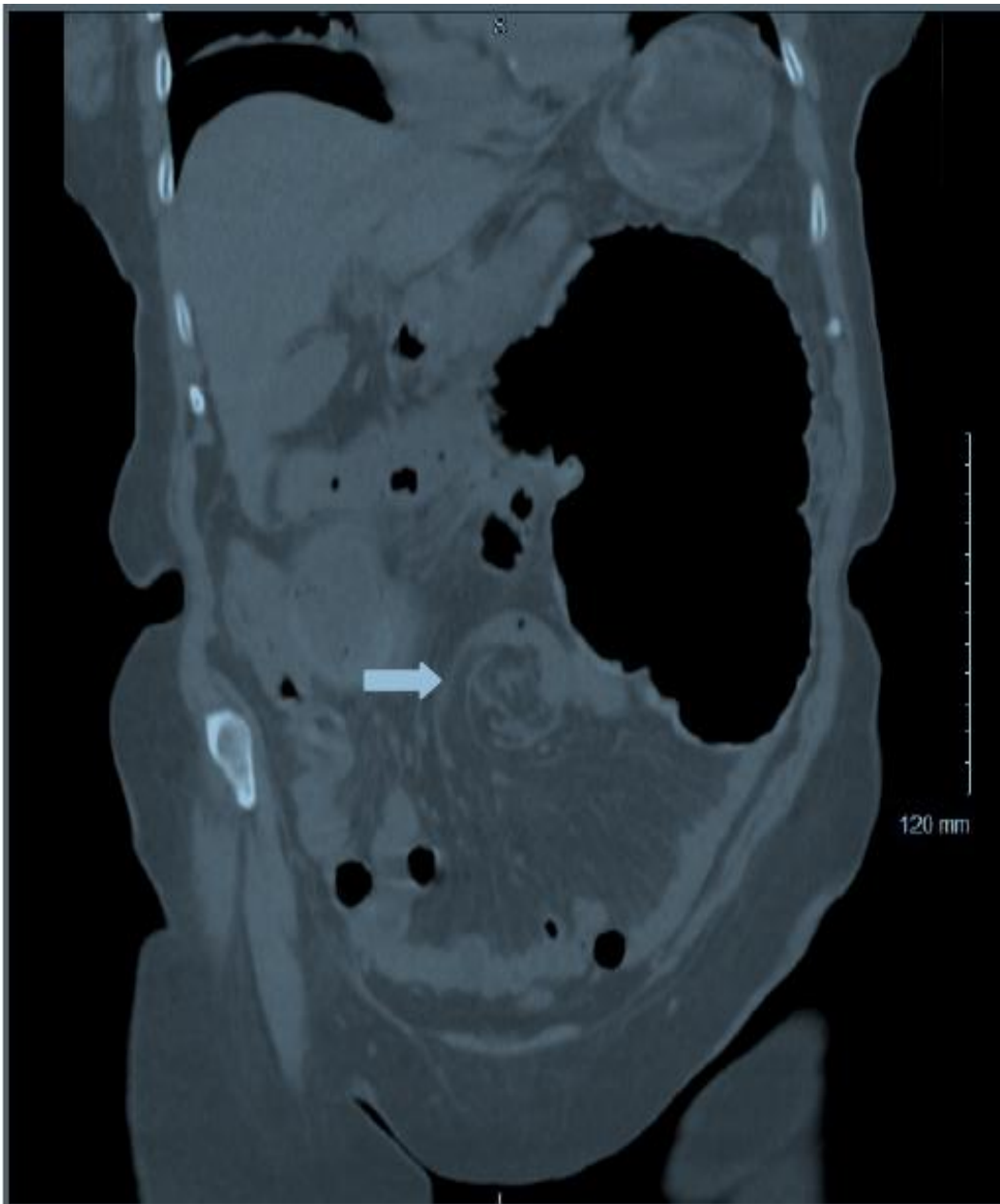
Cecal Volvulus: Clinical Image

Nathan C. Claydon¹, Dustyn Baker¹

¹Sierra Nevada Memorial Hospital, Grass Valley, California, USA

A 77 years old female was sent to the Emergency Department from her primary doctor's office after she complained of 4 days of constipation and abdominal pain. Computed Tomography (CT) scan abdomen was done which showed a Whirl sign indicative of Cecal volvulus. She underwent emergent surgery.

Figure 1: Computed Tomography (CT) scan shows Whirl Sign indicating Cecal volvulus



Conflict of Interest: None declared

This article has been peer reviewed.

Article Submitted on: 18th May 2018

Article Accepted on: 1st June 2020

Funding Sources: None declared

Correspondence to: Dr Nathan C. Claydon

Address: Sierra Nevada Memorial Hospital, Grass Valley, California, USA

Email: nathanclaydon@gmail.com

Cite this article: Claydon NC, Baker D. Cecal volvulus: clinical image. *J Pioneer Med Sci.* 2020; 9(1):1