

# Immunohistochemical Expression of C-erb-B2 and Vimentin in Adenoid Cystic Carcinoma and Polymorphous Low-Grade Adenocarcinoma: A Comparative Study

Mustafa M. Abdulhussain<sup>1</sup>, Muna S. Merza<sup>2</sup>, Mustafa Ghany Taher<sup>3</sup>

<sup>1</sup>M.Sc Oral Pathology, Department of Oral Diagnosis, College of Dentistry, University of Baghdad, Baghdad, Iraq

<sup>2</sup>Assistant Professor, Department of Oral Diagnosis, College of Dentistry, University of Baghdad, Baghdad, Iraq

<sup>3</sup>Assistant Lecturer, M.Sc Oral Pathology, Department of Oral Diagnosis, College of Dentistry, University of Baghdad, Baghdad, Iraq

## ABSTRACT

**BACKGROUND:** The salivary glands tumors are relatively uncommon neoplasms of oral and maxillofacial region with an annual incidence of 2.2 to 2.5 cases per 100,000 in the United States. The aim of the present study was to assess the immunohistochemical expression of two genes, C-erb-B2 (also known as HER-2/neu) and vimentin, in adenoid cystic carcinoma and polymorphous low-grade adenocarcinoma to observe these tumor markers as predictors of grade and stage in salivary gland tumors.

**METHODS:** Thirty consecutive cases, histologically diagnosed as epithelial salivary gland tumors, were included in the study. Fifteen cases were adenoid cystic carcinoma and the remaining cases were polymorphous low-grade adenocarcinoma. Immunohistochemical techniques were used to detect the expression of vimentin and C-erb-B2.

**RESULTS:** We found that C-erb-B2 was

expressed in all (100%) cases of adenoid cystic carcinoma and in 93.3% cases of polymorphous low-grade adenocarcinoma. Normal tissues did not show any staining pattern ( $p < 0.001$ ). The peak incidence of both neoplasms was observed between the fourth to sixth decades of life, males were affected more than females and the palate was the commonest affected site.

There was no significant correlation between C-erb-B2 and vimentin expression with other factors except significant ( $p < 0.05$ ) positive correlation with gender.

**CONCLUSION:** C-erb-B2 is expressed in both tumors compared with the controls suggesting its oncogenic potential. However, we did not find any significant association between C-erb-B2 or vimentin expression and the tumor grade or stage suggesting that these two may be important in oncogenesis but not in determining the tumor grade or stage.

Keywords: Adenoid cystic carcinoma; Adenocarcinoma; C-erb-B2; Vimentin

## INTRODUCTION

Salivary glands are the site of origin of a wide variety of neoplasms. The histopathology of these tumors is considered to be among the most complex and diverse than any organ in the body [1].

Salivary gland neoplasms are also relatively uncommon with an estimated annual incidence in the United States of 2.2 to 2.5 cases per 100,000 people; they constitute only about 2% of all head

and neck neoplasms [1]. Nearly 80% of these tumors occur in the parotid glands, 15% in the submandibular glands and the remaining 5% in the sublingual and minor salivary glands. Benign neoplasms make up about 80% of parotid tumors, 50% of submandibular tumors and less than 40% of sublingual and minor salivary gland tumors. Salivary gland neoplasms are composed of diverse entities of uncertain histogenesis and unpredictable clinical behavior [2-3]. Adenoid cystic carcinoma (ACC) is the second most

Conflict of Interest: None declared

This article has been peer reviewed.

Article Submitted on: 3<sup>rd</sup> December 2012

Article Accepted on: 27<sup>th</sup> July 2013

Funding Sources: None declared

Correspondence to: Dr. Mustafa Ghany Taher

Address: Department of Oral Diagnosis, College of Dentistry, University of Baghdad, Baghdad, Iraq

Email: [mostafa.ghany@yahoo.com](mailto:mostafa.ghany@yahoo.com)

Cite this article:  
Abdulhussain MM, Merza MS, Taher MG. Immunohistochemical expression of C-erb-B2 and vimentin in adenoid cystic carcinoma and polymorphous low-grade adenocarcinoma: a comparative study. *J Pioneer Med Sci.* 2013; 3(4):177-181

common salivary gland malignancy, but is the most common in the submandibular, sublingual and minor salivary glands. It occurs equally in men and women, peaks in the 5th decade of life and is more common in Caucasians [2]. Polymorphous low-grade adenocarcinoma (PLGA) of the salivary glands is rare but aggressive tumor. These tumors tend to clinically present in patients over 40 years of age and occur with nearly equal frequency in men and women. About half of these tumors present in the parotid glands, the minor salivary glands, particularly the palate; lip and tongue are the next most commonly affected sites [2].

The HER-2/neu oncogene is a member of the epidermal growth factor receptor or erb gene family [4] and has an intrinsic tyrosine kinase activity. HER-2/neu was originally identified as a transforming oncogene in chemically induced rat neuroglioblastomas, where a single point mutation in the transmembrane domain of the molecule is sufficient to confer oncogenic activation [5]. Vimentin is a member of the intermediate filament family of proteins. Vimentin plays a significant role in supporting and anchoring the position of the organelles in the cytosol. It provides cells with resilience, absent from the microtubule or actin filament networks, when under mechanical stress in vivo. Therefore, in general, it is accepted that vimentin is the cytoskeleton component responsible for maintaining cell integrity [6-7]. In the present study, we explored the expression of C-erb-B2 and vimentin in ACC and PLGA by immunohistochemical means and sought whether the staining pattern has any association with histological or clinical characters.

## METHODS AND MATERIALS

**Specimens:** Thirty consecutive tissue samples (15 ACC and 15 PLGA), histologically diagnosed as epithelial salivary gland tumors were retrieved from the archives of the Oral Pathology Department, College of Dentistry, University of Baghdad.

Samples used in the study were preserved as formalin fixed paraffin embedded tissue blocks. In each block, one representative section was stained with hematoxylin and eosin for reassessment of histopathological diagnosis and two other sections were prepared on adhesive slides for detection of vimentin and C-erb-B2 by using immunohistochemistry. Normal salivary glands tissue specimens were obtained from five blocks fixed in 10% formalin and processed to

paraffin embedded blocks. Breast adenocarcinoma tissue sections from the teaching laboratories were used as a positive control for both vimentin and C-erb-B2 immunostaining [8]. The negative control slides were prepared from test tissue processed in a manner identical to the test section while omitting the primary antibody and instead adding 20ml of phosphate buffer saline.

**Slide preparation:** Paraffin blocks were cut in 4 microns thick sections for optimum resolution with staining, and then the sections were carried on adhesive slides and left to dry upright in order to facilitate adhesion between the sections and the charged glass surface. The sections were placed on slides as flat and wrinkle free as possible to optimize stain contact with the tissue. The tissue sections were dried on the slides by heating (overnight at 65°C) in a hot air oven to ensure that any moisture trapped under the tissue is completely eliminated by melting the paraffin and evaporation of the water droplets.

The tissue sections were de-paraffinized by dipping into two changes of xylene for 5 minutes at room temperature (xylene jar was placed in the oven few minutes before dipping the slides into it in order to enhance the de-waxing effect). The tissue sections were rehydrated on slides in order to return water to the tissue by dipping slides into ethanol in the following sequential manner:

- Absolute ethanol for 5 minutes.
- 95% ethanol for 5 minutes.
- 70% ethanol for 5 minutes.
- 30% ethanol for 5 minutes.
- Distilled water for 2 minutes.

**Antigen retrieval:** Formalin or other aldehyde fixation forms protein cross-links that mask the antigenic sites in tissue specimens, thereby giving weak or false negative staining for immunohistochemical detection of certain proteins. For the studied antibodies, staining of formalin fixed tissues required pretreatment with citric buffer PH 8.0 in order to break the protein cross-links, therefore unmasking the antigens and epitopes in formalin fixed-paraffin embedded tissue sections, thus enhancing staining intensity of the studied antibodies. The slides were put in koplun jar containing antigen retrieval solution and then the slides in the jar were placed in water bath at 98°C for 10 minutes, then the slides were removed from it, left to cool at room temperature for 20 minutes and placed in distilled water for 5 minutes at room temperature.

**Evaluation of immunohistochemical staining:**

The evaluation of C-erb-B2 immunohistochemical expression was based on a 0-3+ scale as follows:

- 0, staining in < 10% of tumor cells or no staining.
- 1+, faint and partial membrane staining in  $\geq$  10% of tumor cells.
- 2+, weak to moderate complete membrane staining in  $\geq$  10% of tumor cells.
- 3+, moderate to strong complete membrane staining in  $\geq$  10% of tumor cells.

Vimentin expression was determined by evaluating the entire available tumoral tissue in the sections under study. Next, it was determined whether the relative number of positive neoplastic cells was inferior (negative cases) or superior (positive cases) to 10% from all of the neoplastic cells in the histological sections evaluated [9]. The positive cases then were scored into three scores according to degree of positivity:

- 1+ > 10% of cells positive
- 2+ 10- 25% of cells positive
- 3+ > 50% of cells positive

**RESULTS**

Diffuse membranous staining for C-erb-B2 was noted in both malignant tumors while normal salivary gland tissues were not stained with this marker. In breast cancer specimens, C-erb-B2 expression was observed. In PLGA, 2 (13.3%) sections with weak positive expression, 7 (46.7%) sections with moderate positive expression, 5 (33.3%) sections with strong positive expression and only one (6.7%) section with negative expression (Figure 2).

Among vimentin positive ACC specimens, six were of cribriform type; seven were tubular type and two specimens were solid type. We found a non-significant positive correlation between vimentin expression scores and tumor grade. Six vimentin positive specimens were observed in low grade or well-differentiated PLGA, four in moderately differentiated and five cases in poorly differentiated tumors with non-significant correlation.

**DISCUSSION**

This study shows that both malignant tumors (ACC and PLGA) show a significantly greater expression of C-erb-B2 ( $p < 0.001$ ) compared to controls. This supports the hypothesis that C-erb-

**Table 1:** The difference in age and gender distribution between the two types of tumor

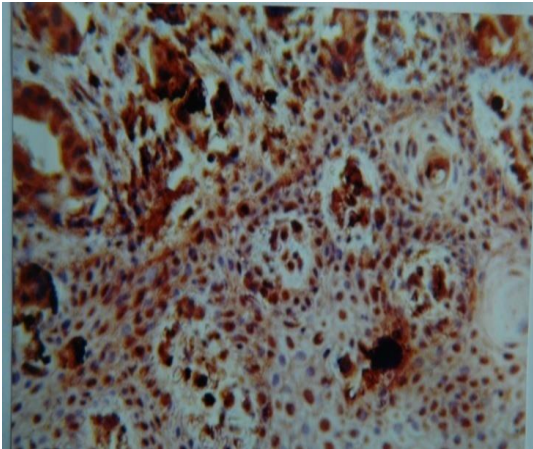
	Tumor type				P
	Adenoid cystic carcinoma		Polymorphous low-grade adenocarcinoma		
	N	%	N	%	
Age in years					0.19[NS]
<40	6	40	3	20	
40-59	6	40	7	46.7	
60+	3	20	5	33.3	
Total	15	100	15	100	
Mean Age +/- SD	43.8 +/-12.5		50.8 +/-15.8		
Gender					0.09[NS]
Female	4	26.7	7	46.7	
Male	11	73.3	8	53.3	
Total	15	100	15	100	

**Table 2:** The difference in median C-erb-B2 proto-oncogene and vimentin expression scores between the two types of tumor

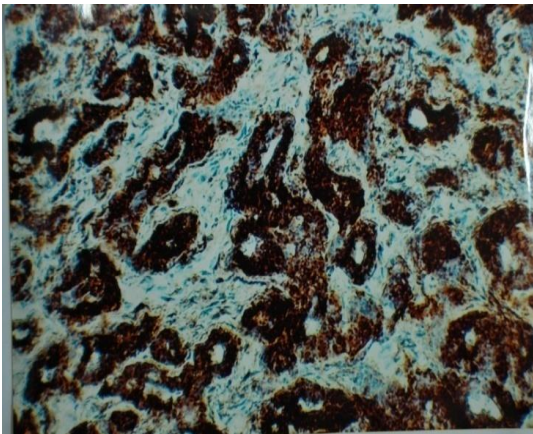
	Tumor type				P
	Adenoid cystic carcinoma		Polymorphous low-grade adenocarcinoma		
	N	%	N	%	
C-erb-B2 proto-oncogene					0.71[NS]
Negative	0	0	1	6.7	
Weak positive	4	26.7	2	13.3	
Moderate positive	7	46.7	7	46.7	
Strong positive	4	26.7	5	33.3	
Total	15	100	15	100	
Median	Moderate positive		Moderate positive		0.35[NS]
Vimentin					
Negative	1	6.7	0	0	
Weak positive	4	26.7	9	60	
Moderate positive	4	26.7	2	13.3	
Strong positive	6	40	4	26.7	
Total	15	100	15	100	
Median	Moderate positive		Weak positive		



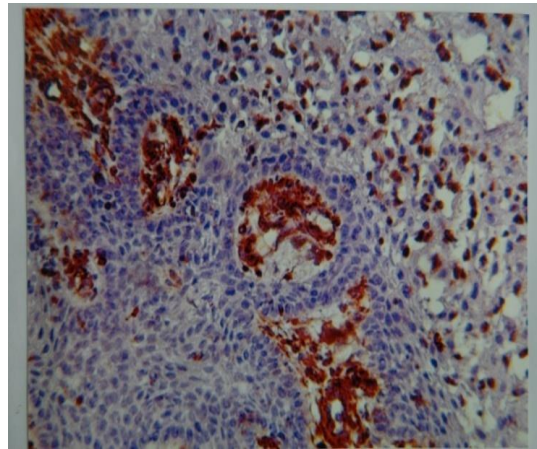
**Figure 1:** Strong positive C-erb-B2 immunohistochemical expression in adenoid cystic carcinoma, high grade (X20)



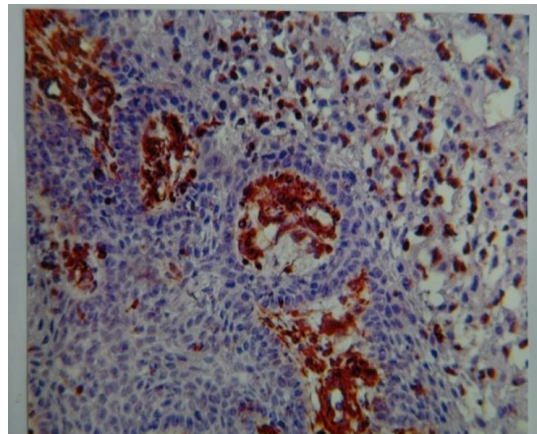
**Figure 2:** Strong positive C-erb-B2 immunohistochemical expression in poorly differentiated polymorphous low-grade adenocarcinoma (X20)



**Figure 3:** Strong positive vimentin immunohistochemical expression in adenoid cystic carcinoma, low grade (X20)



**Figure 4:** Strong positive vimentin immunohistochemical expression in, moderately differentiated polymorphous low-grade adenocarcinoma (X20)



B2 expression may confer oncogenic properties to these malignant tumors. However, within the tumor samples, the correlation of positive staining (weak, moderate and strong) with histological grading was non-significant.

ACC is the most common malignant tumor of minor salivary glands, submandibular and sublingual glands. It has a peak incidence in the fourth to sixth decades of life, which is in accordance with what we found (Table 1), [10, 11]. The mean patient age in our study was 58 years which is consistent with previous reports [1]. The association of oral cancer development with aging could be explained by the prolonged exposure to environmental carcinogenesis such as radiation, viruses and chemicals which play as prompting factors in cancer development. The res-

ults of the present study concerning gender distribution come in accordance with some previous reports [12] but in contrast to others [13]. We found that males were more affected with these malignant salivary gland tumors than females (Table 1). Similar findings were reported from other parts of the world, including Iraq, which found that 55% of patients with malignant salivary gland tumors were males [14, 15]. In contrast to this, other studies did not find a gender predisposition [1]. This difference may be attributed to the small sample size of this study and the higher frequency of smoking in males than females. Another possible explanation for such discrepancy is due to the variation in the method of data collection and the types of the samples used in different studies.

The distribution of ACC and PLGA lesions according to the site revealed that the palate was the commonest site affected with these malignant tumors. This finding was in agreement with previous studies that the effect of smoking habit especially the pipe smoking generates more heat on the palate than other forms of smoking and produces a pronounced palatal keratosis or reverse smoker's palate, which has a significant potential to develop into dysplasia or carcinoma. Our results revealed positive C-erb-B2 expression in all cases of ACC with strong positivity in 26.7% of cases, and in 93.3% of PLGA cases with 33.3% of the cases showing strong positive expression; these results are also consistent with previous reports [16, 17, 18].

## CONCLUSION

In conclusion, we did not find any significant association between C-erb-B2 and vimentin staining and the histological characteristics of the tumors. Further studies should identify other immunohistochemical markers, which are predictive of grading and staging.

## REFERENCES

1. Ellis GL, Auclair PL. Tumors of the salivary glands. Atlas of tumor pathology. Fascicle 17. Washington DC: Armed Forces Institute of Pathology 1996; 203–228.
2. Eisele DW, Johns ME. Salivary Gland Neoplasms. Ed, BJ Bailey. Philadelphia, Lippincott Williams & Wilkins 2001; 1279-1297.
3. Dardick I, Gliniecki MR, Heathcote JG, Burford-Mason A. Comparative histogenesis and morphogenesis of mucoepidermoid carcinoma and pleomorphic adenoma: an ultrastructural study. *Virchows Arch A Pathol Anat Histopathol* 1990; 417:405-417.
4. Navolanic PM, Steelman LS, McCubrey JA. EGFR family signaling and its association with breast cancer development and resistance to chemotherapy. *Oncol* 2003; 22:237–252.
5. Shih C, Padhy LC, Murray M, Weinberg RA. Transforming genes of carcinomas and neuroblastomas introduced into mouse fibroblasts. *Nature* 1981; 290:261-264.
6. Fuchs E, Weber K. Intermediate filaments structure dynamics function and disease. *Annu Rev Biochem* 1994; 63:345–82.
7. Goldman RD, Khuon S, Chou Y, Opal P, Steinert P. The function of intermediate filaments in cell shape and cytoskeletal integrity. *J Cell Biol* 1996; 134:971–983.
8. Classen S, Kopp R, Possinger K, Weidenhagen R, Eiermann W, Wilmanns W. Clinical relevance of soluble c-erbB-2 for patients with metastatic breast cancer predicting the response to second-line hormone or chemotherapy. *Tumour Biol* 2002; 23:70–75.
9. Genelhu MC, Cardoso SV, Gobbi H, Cassali GD. A comparative study between mixed-type tumours from human salivary and canine mammary glands. *BMC Cancer* 2007; 7:218.
10. Ihrler S, Blasenbren-Vogt S, Sendelhofert A, Lang S, Zietz C, Löhns U. Differential diagnosis of salivary acinic cell carcinoma and adenocarcinoma (NOS). A comparison of (immuno)histochemical markers. *Pathol Res Pract* 2002; 198:777-783.
11. Giannini PJ, Shetty KV, Horan SL, Reid WD, Litchmore LL. Adenoid cystic carcinoma of the buccal vestibule: A case report and review of the literature. *Oral Oncol* 2006; 42:1029–1032.
12. Tomich CE, Ellis GL, Aclair PL, Gnepp DR. Adenoid cystic carcinoma. Surgical pathology of the salivary glands. Philadelphia, PA:Saunders 1991; 333-349.
13. Perzin B, Caruana SM, Huvos AG. Small cell neuroendocrine carcinoma of the nasal cavity and paranasal sinuses. *Hum Pathol* 1978; 29:826-832.
14. Hussain QA. In situ hybridization and proliferating cell nuclear antigen immunohistochemical expression in salivary gland tumors. A Master thesis submitted to College of Dentistry, University of Baghdad, 2007.
15. Ali MK. Immunohistochemical expression of matrix metalloproteinase-2 with its tissue inhibitor in pleomorphic adenoma and adenoid cystic carcinoma. A Master thesis submitted to College of Dentistry, University of Baghdad, 2008.
16. Press MF, Pike MC, Hung G, Zhou JY, Ma Y, George J, et al. Amplification and overexpression of HER-2/neu in carcinomas of the salivary gland: correlation with poor prognosis. *Cancer Res* 1994; 54:5675-5682.
17. Giannoni C, el-Naggar AK, Ordonez NG, Tu ZN, Austin J, Luna MA, Batsakis JG. c-erbB-2/neu oncogene and Ki-67 analysis in the assessment of palatal salivary gland neoplasms. *Otolaryngol Head Neck Surg* 1995; 112:391–398.
18. Khan AJ, Digiovanna MP, Ross DA, Sasaki CT, Carter D, Son YH, et al. Adenoid cystic carcinoma: a retrospective clinical review. *J Cancer* 2001; 96:149–158.