

# Hiatal Hernia - A Coincidence or Causative Factor for Idiopathic Pulmonary Fibrosis?

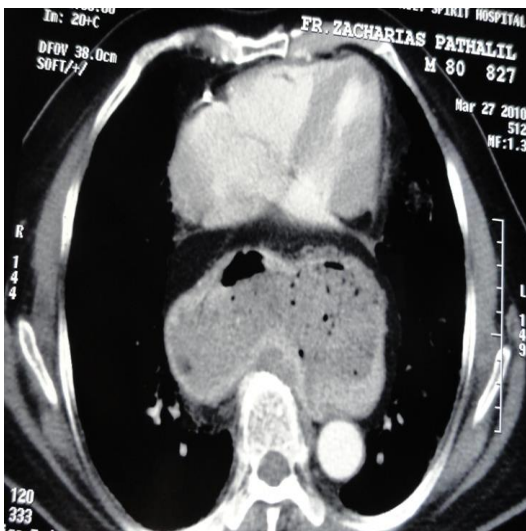
Sudarsan Pothal<sup>1</sup>

<sup>1</sup>Assistant Professor, Department of Pulmonary Medicine, V.S.S. Medical College, Odisha, India

## BRIEF HISTORY

An 80-year-old male, non-smoker, non-alcoholic, and a priest by profession presented with history of progressive breathlessness and dry cough since nine months along with symptoms of gastro-esophageal reflux disorder (GERD). There was no past history of any other disease or medication. On clinical examination, there was tachycardia and tachypnea; the patient was normotensive but hypoxic with digital clubbing and bilateral inspiratory fine crepitations at basal region. Routine hematological examination was normal. Chest X-ray showed bilateral reticular shadows at lower zone. Spirometry findings showed moderate restrictive pathology. CT scan of thorax showed reticular opacities predominantly in the peripheral, subpleural and bibasilar regions along with interlobular septal thickening, subpleural honeycombing and traction bronchiectasis which was suggestive of usual interstitial pneumonia pattern of interstitial lung disease with hiatal hernia (Figure 1 and 2). Serological profile including ANA, rheumatoid factor and CRP did not show any feature of connective tissue disorder. Upper GI endoscopy was suggestive of hiatal hernia. Our final diagnosis was idiopathic pulmonary fibrosis

**Figure 1:** CT scan thorax (mediastinal window) showing hiatal hernia



(IPF) with hiatal hernia.

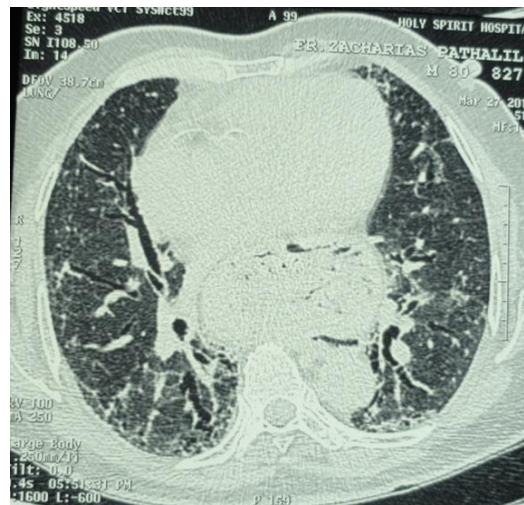## DISCUSSION

IPF is a complex disease with an unknown etiology. The current hypothesis suggests an alveolar epithelial injury followed by repair involving serial lung injury and aberrant repair [1]. GERD has been recognized as a risk factor and may have a role in the pathogenesis of IPF probably through micro-aspiration [2, 3]. In general, micro-aspiration due to reflux is associated with the presence of hiatus hernia [4], which is known to alter the integrity of the lower esophageal sphincter. Therefore, it is possible that hiatal hernia could be a contributor to IPF. Hiatal hernia may also be the result of lung restriction in IPF leading to displacement of the diaphragm in patients with IPF [5].

## REFERENCES

1. Harari S, Caminati A. Idiopathic pulmonary fibrosis. *Allergy* 2005; 60:421-435.
2. American Thoracic Society, European Respiratory Society. American Thoracic Society/European Respiratory Society International Multidisciplinary Consensus Classification of the Idiopathic Interstitial Pneumonias. *Am J Respir Crit Care Med* 2002;

**Figure 2:** CT scan thorax showing traction bronchiectasis, interlobular septal thickening and subpleural honeycombing



Conflict of Interest:  
None declared

This article has been  
peer reviewed.

Article Submitted on:  
24<sup>th</sup> February 2013

Article Accepted on: 27<sup>th</sup>  
July 2013

Funding Sources: None  
declared

Correspondence to: Dr.  
Sudarsan Pothal

Address: Department of  
Pulmonary Medicine,  
V.S.S. Medical College,  
Burla, Sambalpur,  
Odisha, India

Email:  
[pothal2002@yahoo.co.in](mailto:pothal2002@yahoo.co.in)

Cite this article: Pothal S.  
Hiatal hernia - a  
coincidence or causative  
factor for idiopathic  
pulmonary fibrosis? *J  
Pioneer Med Sci.* 2013;  
3(4):162-163

- 165:277-304.
3. Raghu G. The role of gastroesophageal reflux in idiopathic pulmonary fibrosis. *Am J Med* 2003; 115:60S-64S.
  4. Fein M, Ritter MP, DeMeester TR, Oberg S, Peters JH, Hagen JA, et al. Role of the lower esophageal sphincter and hiatal hernia in the pathogenesis of gastroesophageal reflux disease. *J Gastrointestinal Surg* 1999; 3:405-410.
  5. Linden PA, Gilbert RJ, Yeap BY, Boyle K, Deykin A, Jaklitsch MT, et al. Laparoscopic fundoplication in patients with end-stage lung disease awaiting transplantation. *J Thorac Cardiovas Surg* 2006; 131:438-446.