

Use of the lightwand (Trachlight™) as an aid to tracheal intubation in patient with limited mouth opening and failed Macintosh laryngoscopy

Amal al-Siyabi¹, Rashid Manzoor Khan², Naresh Kaul², Awad Othman Abdul-Razik², Sujit Nair²

¹ First Year Anesthesia Resident

² Consultant/Specialist, Department of Anesthesia & Intensive Care Unit, Khoula Hospital, Muscat, Oman

ABSTRACT

A 50-year-old male patient with multi-organ failure and gangrene of the face was brought to the operation theater for an emergency debridement of the gangrenous tissue. Poor oral hygiene with loose teeth and limited mouth opening led to failure of rigid Macintosh laryngoscopy. Fiberoptic tracheal intubation was not adopted as an intubating aid as the patient was suspected of having pulmonary tuberculosis and

there was a risk of equipment contamination. Lightwand (Trachlight™) assisted tracheal intubation proved successful on the first attempt under general anesthesia despite the difficult airway of the patient. During lightwand assisted tracheal intubation, patient maintained good oxygenation as he continued to receive apneic oxygenation via a nasal catheter.

Key words: Lightwand, Difficult tracheal intubation, Trachlight™

Conflicting Interest:
None declared

This article has been peer reviewed

Article Submitted on: 15th April 2011

Article Accepted on: 19th May 2011

Funding sources:
None declared

Correspondence to
Dr. Naresh Kaul, MD

Address: PO Box 96,
PC 118, Al Harthy
Complex, Sultanate
of Oman

E-mail:
nassn@omantel.net.om,
drnareshkaul@qmail.com

CASE REPORT

A 50-year-old American Society of Anaesthesiology grade III male weighing 50 kg presented with gangrene of the upper lip, left cheek and left alae nasi. There was an accompanying left-sided intraoral swelling extending to the left temporomandibular joint and periorbital area (Figure 2) as seen through limited mouth opening. Mouth opening was limited to less than 2 cms.

On history and physical examination, the patient was poorly controlled diabetic and a known case of pulmonary tuberculosis with cavitations in the right upper lobe of the lung as seen in PA view of X-ray chest. He had taken anti-tubercular treatment for one week and then stopped it few weeks prior to presentation. The patient also had end-stage renal failure, cirrhosis of the liver, and idiopathic thrombocytopenic purpura. He was short of breath, appeared sick, preferred semi-sitting in his bed and was uncooperative. On examination, he had crepitation and wheezing over the right lung field. His oral hygiene was poor and he had irregularly located loose teeth. Mallampati grading was III but this could have been influenced by limited mouth opening. On the day of surgery, his coagulopathy was corrected by the administration of 4 units of fresh

frozen plasma. An insulin infusion was started and his preoperative blood sugar was 9.2 mmol/L. Patient was scheduled for emergency excision and debridement of gangrene.

Anesthesia was induced with gradually increasing concentration of sevoflurane (1-6%) in 100% oxygen in spontaneously breathing patient. After reaching adequate depth of anesthesia, gentle Macintosh laryngoscopy was performed. Limited size of oral orifice persisted and glottis or epiglottis were not visible. Rigid Macintosh laryngoscopy was abandoned. Having ascertained no problem with assisted mask ventilation, it was now decided to administer 50µg remifentanyl and paralyze the patient with 50mg succinylcholine before attempting Trachlight™ aided tracheal intubation. However, keeping in mind poor respiratory reserve of the patient, a 14Fr suction catheter was placed through the right nostril into the oropharynx and 3 L/min oxygen was administered via this catheter to prevent rapid oxygen desaturation (Figure 3). With gentle manipulation, Trachlight™-endotracheal tube assembly (TEA) entered the glottis as evidenced by a light glow over the larynx (Figure 4). TEA was pushed further till the light

glow just disappeared below the suprasternal notch. Clamp of the Trachlight™ holding the endotracheal tube was now released and Trachlight™ removed. Thereafter, breathing circuit was attached and correct tracheal tube placement was confirmed by capnography. Endotracheal tube was fixed appropriately to prevent any dislodgment. During the entire period of Trachlight™ aided tracheal intubation procedure, which lasted 40 seconds, patient's oxygen saturation remained over 96%. Surgery proceeded uneventfully. At the conclusion of surgery, patient's trachea was extubated after reaching a wakeful state. Patient underwent another uneventful debridement 3 days later using the trachlight again for intubation.

DISCUSSION

There are several guidelines and algorithms which help to facilitate management of patients with known difficult airway [1-3]. However, none of these guidelines and algorithms suggests a specific technique or a step-wise approach to a patient with predicted difficult tracheal intubation. There are occasions where several contraindications prevent anesthesiologists from utilizing airway aids of their first choice. These limitations have been highlighted in the present case report. We further present one strategy to overcome these limitations successfully using a lightwand (Trachlight™, Laerdal, Armonk, NY: Figure 1).

First limitation was that our patient was very uncooperative and therefore, we could not perform an awake tracheal intubation; a method strongly advocated by various airway management guidelines [1-3]. Secondly, we could not use flexible fiberoptic, an ideal device for intubation of a patient with limited oral opening, as our patient had untreated cavitary pulmonary tuberculosis [4, 5]. Although the infectivity status of pulmonary tuberculosis was not known on the day of emergency surgery, we had to consider using something other than the only adult flexible fiberoptic available in the operation theatre due to the risk of its contamination by mycobacterium tuberculosis.

In this patient our primary tracheal intubation strategy was using the rigid Macintosh laryngoscope. We had three backup plans of using Trachlight™ (Plan – A) or placing a supraglottic device like Laryngeal Mask Airway (Plan – B) or performing cricothyrotomy (Plan – C) using Melker's™ emergency cricothyrotomy catheter set (Cook Medical Incorporated, Bloomington, IN, USA) in the event of failed tracheal intubation and / or ventilation by the primary method. Though we failed with our primary strategy, our first backup plan succeeded and a secured airway was achieved.

Unfortunately, a preliminary rigid Macintosh laryngoscopy by a senior anesthesiologist failed. Among the factors responsible for failure were the loose, irregular teeth that made rigid Macintosh

laryngoscopy difficult, limited mouth opening, and facial edema. After failed attempt with Macintosh laryngoscope, we decided to use Trachlight™, a lightwand. Lightwand tracheal intubation is a technique in which an illuminated malleable stylet is passed into the endotracheal tube, and the combined endotracheal tube-lightwand assembly is guided into the trachea by transillumination of the neck tissue. This technique of tracheal intubation has been successfully used in patients with limited mouth opening, restricted cervical spine movement, orofacial distortions, or unexpected failed intubation [6, 7]. There are several modifications of lightwand available for clinical use (Tube-Stat™, Imagica™, or the more commonly used Trachlight™).

Our 1st backup plan was thus Trachlight™ aided tracheal intubation since we had the requisite expertise and the facial edema was restricted to the left side of the face leaving a free midline space to manipulate the device. While Trachlight™ aided tracheal intubation may be attempted in a spontaneously breathing patient, such patients on an average require 3 attempts [8]. It was therefore decided to paralyze the patient with succinylcholine, a short acting depolarizing muscle relaxant, to facilitate rapid tracheal intubation with the Trachlight™.

Another objective for using a paralyzing agent was to help in achieving a better mouth opening. Despite a relatively poor transillumination, due to dark

skin color of the patient and continued limitation in opening mouth, successful Trachlight™ tracheal intubation was safely achieved. While undertaking Trachlight™ aided tracheal intubation in this patient, we delivered supplemental oxygen via nasal catheter throughout the process to prevent oxygen desaturation in an apneic patient. This or any other such oxygen supplementation strategy is highly recommended during difficult airway management [9, 10].

In conclusion, this case report highlights the need to plan strategies according to individual patient's need. Further, it re-enforces the dictum of airway management to always have backup plans to fall upon in case of failure of the primary plan. This case report also re-establishes the fact that Trachlight™ is a useful aid in patients with difficult airway. Lastly, Trachlight is a cost effective airway device as the wand can be discarded after use in patients with resistant infection.

Note: The department had secured the permission of the patient to use his photograph for academic purposes before the first surgical intervention.

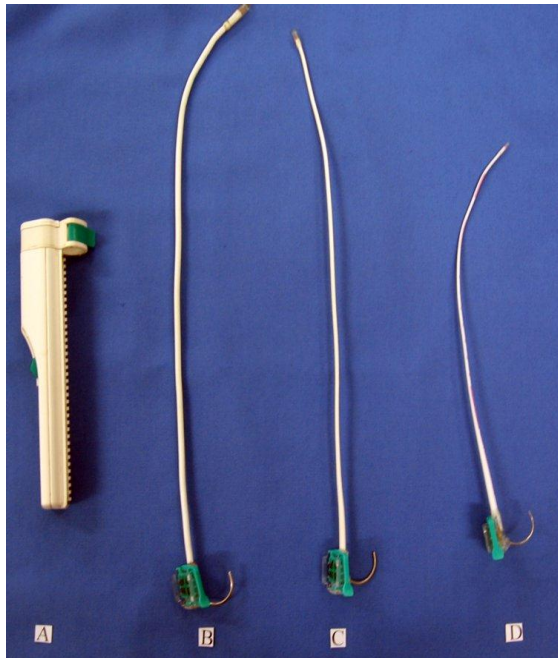


Figure 1: showing the Trachlight handle and the 3 sizes of the wands

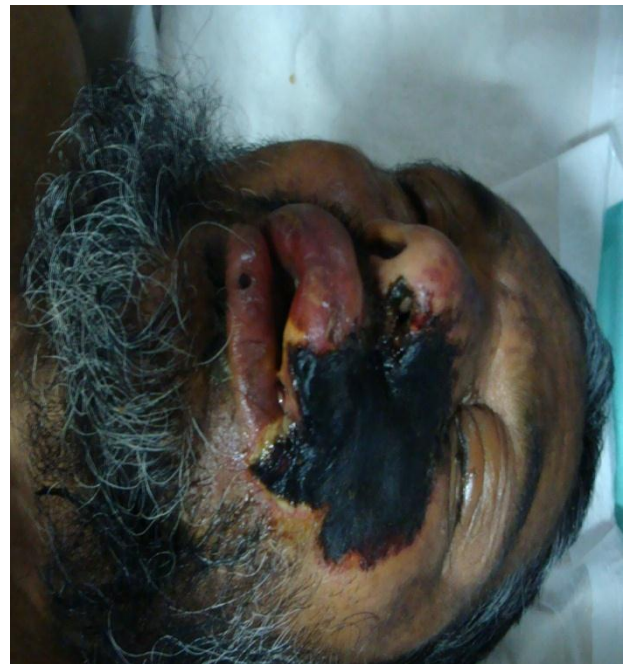

Figure 2: showing left sided gangrene of the lip, cheek and ala nasi with edema extending to the periorbital area

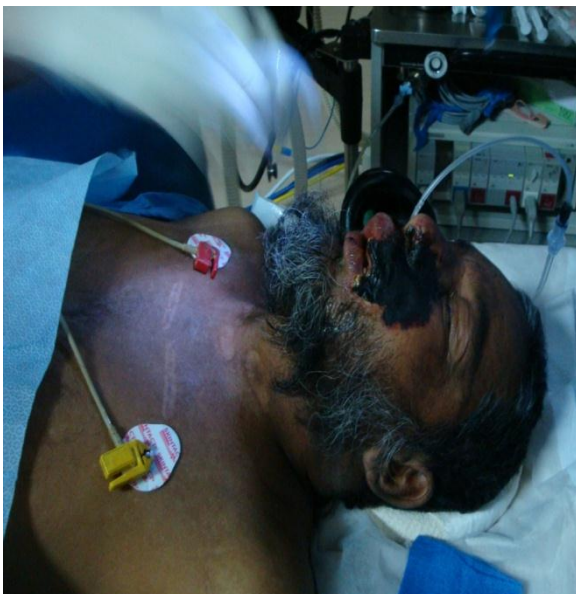

Figure 3: showing oxygen insufflation via the right nostril

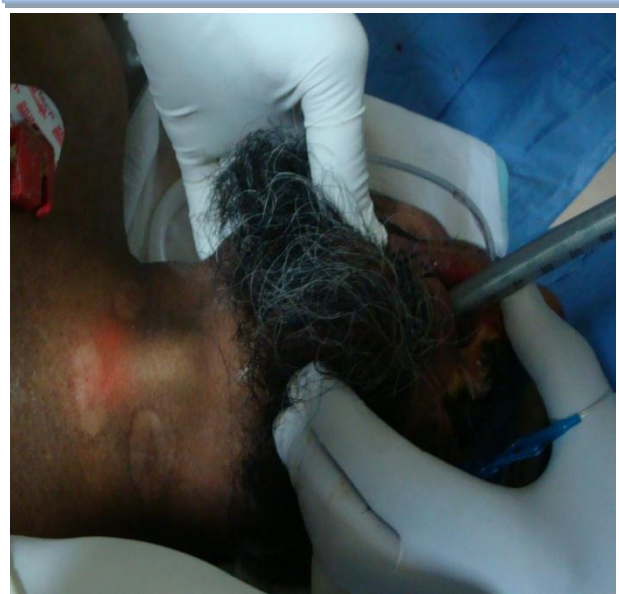

Figure 4: showing the light glow at the level of suprasternal notch

REFERENCES

1. Practice guidelines for management of the difficult airway. An updated report by American Society of Anesthesiologists Task Force on Management of the Difficult Airway. *Anesthesiology* 2003; 98: 1269-77.
2. Crosby ET, Cooper RM, Douglas MJ et al. The unanticipated difficult airway with recommendations for management. *Can J Anesth* 1998; 45: 757-76.
3. Henderson J, Popat M, Latto P, Pearce A. Difficult Airway Society Guidelines-Update. *Anaesthesia* 2004; 59: 1242-3.
4. Edens ET, Sia RL: Flexible fiberoptic endoscopy in difficult intubations. *Ann Otol Rhinol Laryngol* 1981; 90:307-9.
5. Ovassapian A, Wheeler M. Fiberoptic endoscopy-aided techniques. In: Benumof JL, ed. *Airway Management: Principles and Practice*, St.Louis: Mosby; 1996: 282-319.
6. Hartman RA, Castro T Jr, Matson M, Fox DJL. Rapid orotracheal intubation in the clenched-jaw patient: A modification of the lightwand intubation technique. *J Clin Anesth* 1992; 4: 245-6
7. Hung OR, Pytka S, Morris I, Murphy M, Stewart RD. Lightwand intubation: II. Clinical trial of a new lightwand for tracheal intubation in patients with difficult airways. *Can J Anesth* 1995; 42: 826-30
8. Eva M, Sergi S, Marta H, Pere V, Jaume C, Olivier L. Lightwand tracheal intubation with and without muscle relaxant. *Anesthesiology* 2006; 104: 249-54
9. Teller LE, Alexander CM, Frumin MJ, et al: Pharyngeal insufflation of oxygen prevents arterial desaturation during apnea. *Anesthesiology* 1988; 69: 980.
10. Berry JM. Conventional orotracheal and nasotracheal intubation (single lumen tube). In: Hagberg CA, Eds. *Benumof's Airway Management*, 2nd ed. New York: Mosby Inc, 2007.