

Epidermoid Cysts in the Frontal Lobe – A Case Series

Hina Abdul Qayoom Khan¹, Zain A. Sobani², Arshad A. Siddiqui³

¹ Department of Surgery, Jinnah Post-graduate Medical Center, Karachi, Pakistan

² Section of Neurosurgery, Department of Surgery, Aga Khan University, Stadium Road, Karachi, Pakistan

³ Pakar Neurosurgery, Hospital Sultanah Aminah, Johor Bahru, Malaysia

ABSTRACT

BACKGROUND: Intracranial epidermoid tumors account for approximately 1% of the intracranial tumors. These tumors are thought to arise from displaced epithelial remnants after the neural tube closure. These tumors are usually benign intradural but extracerebral lesions and are rarely found within the substance of the brain. Even more rare location for epidermoid tumors is fronto-ethmoidal. To the best of our knowledge, only 28 cases have been reported in this location so far.

CASES: Here we report two cases of middle-aged men presenting with recurrent headaches, which were associated with behavioral changes and seizures. Both men were diagnosed with fronto-ethmoidal epidermoid cysts, which were surgically excised.

Surgical excision was easily established due to the avascular nature of the tumor. However, the tumor capsules had to be left behind due to adhesions with vital structures. On follow-up visits, the patients were asymptomatic and were living without any residual symptoms.

CONCLUSION: Surgical resection appears to be the mainstay of treatment; however, the extent of resection is dictated by adherence of the tumor capsule to the surrounding vital structures. The advantages of aggressive neurosurgical intervention must be weighed against an acceptable risk of neurological complications. Given the indolent growth pattern, subtotal resection is also acceptable.

Key words: Epidermoid Cyst; Frontal Lobe; Case Series

Conflicting Interest:
None declared

This article has been
peer reviewed.

Article Submitted
on: 7th July 2011

Article Accepted on:
3rd August 2011

Correspondence to
Dr. Arshad
A.Siddiqui

Address:
Pakar Neurosurgery,
Hospital Sultanah
Aminah, Jalan Abu
Bakar, Johor Bahru
80100, Malaysia

E-mail:
doc4brains@yahoo.com

INTRODUCTION

Intracranial epidermoid tumors first described by Bailey[1] and Cushing[2] in the early 1920s, account for nearly 1% of the intracranial tumors.[3-5] Thought to arise from displaced epithelial remnants that remain after the neural tube closure, these tumors are usually congenital; however, acquired lesions are rarely reported.[4, 6]

These are usually benign intradural but extracerebral lesions and are rarely found within the substance of the brain. Furthermore, fronto-ethmoidal location of epidermoid is rare. Our review of the Medline and Google Scholar databases revealed 28 reported cases. Here we report two cases of frontal lobe epidermoid tumors with specific emphasis on pre-operative radiological features and operative findings.

CASE SUMMARIES

Case-1

A thirty-year old male presented in the outpatient clinic with complaints of progressively worsening headaches for the past 5 months. The headaches were mild to moderate in intensity and were worse early in the morning. Headaches improved with over-the-counter analgesics. The headaches were also associated with nausea, retching and behavioral changes (mainly forgetfulness). There was no history of seizures, fever, or visual disturbances. His neurological examination was essentially unremarkable, except that his Mini-Mental State (MMS) examination revealed a score of 23 out of 30.

The patient had previously undergone Magnetic Resonance Imaging (MRI), which revealed a mass lesion of about 7.5 x 6.0 x 5.5 cm in dimension, located at the right frontal lobe along the anterior part of falx cerebri. The lesion was producing homogenous hypointense signals on T1-weighted images, while it produced heterogeneous bright signals on T2-weighted images. There was no post-gadolinium enhancement of the lesion [Figure 1]. The above findings were suggestive of an epidermoid cyst.

The patient underwent a right frontal craniotomy. After opening the dura, a pearly white mass was found with a well-demarcated interface with cerebral surface. The mass was avascular and was easily excised by a suction catheter. A near-total excision was achieved but the capsular membrane had to be left behind as it was adherent to the surrounding cerebral tissue.

Histopathological examination of the excised tissue confirmed the diagnosis of epidermoid cyst with keratinous crystals. The patient's post-operative recovery was un-eventful and he was discharged on the 7th post-operative day.

On follow-up, the patient claimed a remarkable subjective improvement. His headaches had also resolved. At his 6-month follow-up visit, his MMS examination revealed a score of 26/30.

Case-2

A twenty-year old male presented to our emergency department with generalized tonic clonic seizures associated with loss of consciousness, frothy discharge from mouth and urinary incontinence. There was no history of fever, visual disturbances or trauma.

On examination, he was drowsy but arousable with a Glasgow Coma Scale (GCS) of 13/15. There were no other neurological deficits and the systemic examination was within normal limits. As per hospital protocol, he was started on intravenous phenytoin. A careful review of the patient's history revealed that he had complained of mild headaches, which were relieved by over-the-counter analgesics.

Computerized Tomography (CT) scan showed a cystic midline lesion extending into the anterior fronto-basal regions bilaterally. The walls of the lesion were hyperdense on the right side. There was no post-contrast enhancement on the CT scan [Figure-2]. MRI revealed a 4.5 x 2.5 x 3.0 cm lesion, which was hypointense on T1-weighted sequences and hyperintense on T2-weighted sequences. There was no post-contrast enhancement [Figure 3]. These features were suggestive of an epidermoid cyst.

After 48 hours, the patient was clinically stable and underwent a bifrontal craniotomy. The mass was filled with pearly white material and was easily

removed using a suction catheter. Due to the avascular nature of the mass, it was possible to achieve near-total excision, leaving only the adherent membranous lining behind.

His post-operative recovery was uneventful. Histopathological examination confirmed the diagnosis of an epidermoid cyst. At 3-month follow up, the patient had no complaints and his seizures were well controlled on a maintenance dose of phenytoin.

DISCUSSION

Since their initial description, epidermoid cysts have been well studied and the natural history of the disease is well described. These benign tumors of embryonal origin are formed between the 3rd and 5th weeks of embryonic development due to the displaced epithelial remnants that persist after neural tube closure.[7, 8] They are often found where two ectodermal surfaces fuse such as the skin, epidural, intradiploic and epicranial tissue.(9)

Within the domain of neurosurgery, they commonly occur in isolation at the cerebellopontine angle (37%), suprasellar region (31%), diploic (16%), rhomboid fossa (11%) and spinal canal (5%),[10] accounting for approximately 1% of all the intracranial tumors.[3-5] Less common locations include the pineal gland, thalami, septum pellucidum and other intraparenchymal locations. In rare cases, they have been reported in other locations such as the lateral ventricles.[10]

Epidermoids are generally slow-growing lesions, remaining asymptomatic for long periods of development. Patients generally present with symptoms between the ages of 20-40 years.[11] The presenting symptoms mainly depend on the location and the mass effect of the lesion rather than the natural disease process.[10] Patients with frontal lobe tumors can present with dementia secondary to obstructive hydrocephalus or the local effect of the tumor.[6] Our first patient presented with a low MMS score, which could be attributable to the local effects of the tumor. The presentation of the second case with seizures is an extremely rare presenting symptom. In fact, we found only two other cases in our review of literature of patients presenting with seizures.[8, 12] The mechanism resulting in seizures is unknown; however, we hypothesize that this maybe attributable to direct cerebral compression by the expanding cyst.

MRI appears to be the best modality for radiological evaluation of these tumors. Typically epidermoid tumors are hypointense on T1-weighted and hyperintense on T2-weighted images with long relaxation times. Due to the low vascularity of these tumors, no post-contrast enhancement is noted. Fluid-Attenuated Inversion Recovery (FLAIR)

sequences help distinguish them from similar-appearing arachnoid cysts, as the former are hyperintense. Diffusion-weighted images further enhance the accuracy of preoperative diagnosis.[12-14] Calcifications may be seen within these tumors in 10%–25% of cases.[9]

Surgical excision is the mainstay of treatment, and is low-risk due to the avascular nature of the tumor. As seen in our case-series, we were able to debulk most of the tumor by a suction catheter. Surgical planning and extent of resection is based on fundamental neurosurgical principles, where preservation of vital structures is followed by maximal debulking. The capsule of the cyst can be problematic in this case as it may be adherent to vital structures and may need to be left behind. The implications of leaving the cyst wall behind include a recurrence of the mass; however, this may be acceptable due to the benign nature of the disease and the indolent pattern of growth giving the patient a long symptom-free interval. Even with subtotal resection of the mass, a mean symptom-free interval of 8 years has been reported.[15] This period can further be enhanced by aggressive resection of the tumor and its capsule; however, it must be balanced within reasonable limits of acceptable risk for neurological deficits.

Although benign in nature, these masses have been shown to undergo malignant change.[16-20] On turning malignant, the course of the disease changes rapidly and severe deterioration is noticed. Malignant transformation can be detected by contrast

enhancement of the previously avascular tumor.

Hamlat et al. while studying malignant degeneration of the remnant lesion, reported that from the seventeen cases undergoing malignant degeneration, six showed enhancement at the time of the initial CT study,[21] indicating that post-contrast enhancement may warrant more aggressive excisional strategies.

When considering complications of surgical excision, Roy et al. while analyzing 28 cases of intracranial epidermoids, reported the unfortunate demise of five patients. Other postoperative complications included chemical meningitis in 7, worsening of cerebellar function in 3 and aggravation of cranial nerve deficits in 2 patients. All of the deficits except for one case of cranial nerve deficits resolved with time.[22] In cases of midline front-basal location, Barnett FC et al. reported continued anosmia and mild neuro-cognitive dysfunction with no new deficits,[6] while in our cases as well as those of Iaconetta et al., the recovery was without any complications.[12]

CONCLUSION

Intracranial epidermoid tumors are rarely found in the frontal lobes. Surgical resection appears the mainstay of treatment; however, the extent of resection is dictated by the adherence of the tumor capsule to surrounding vital structures. The advantages of aggressive neurosurgical intervention must be weighed against an acceptable risk of neurological outcomes. Due to indolent growth pattern, subtotal resection is also acceptable.

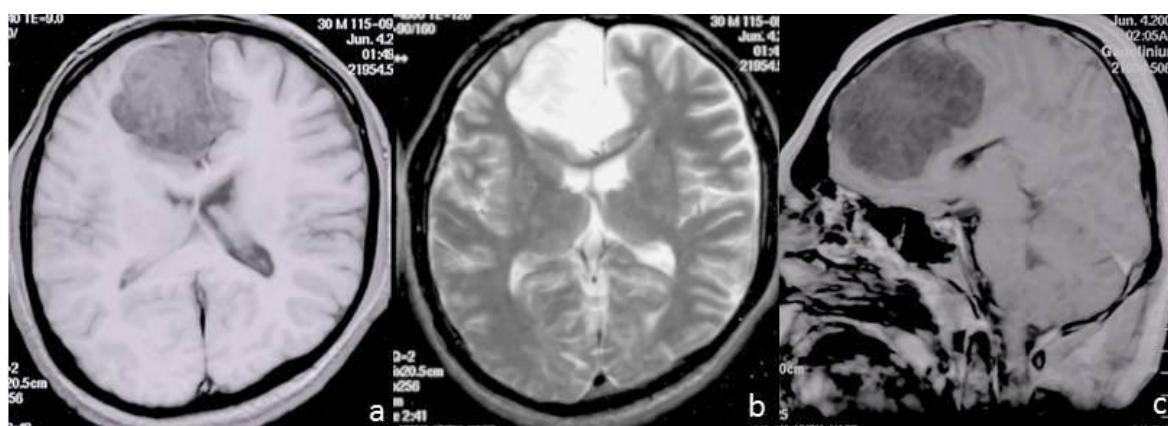


Figure 1: MRI brain of patient 1, (a) T-1 weighted image (axial section) showing a hypointense mass lesion in the right frontal region with subfalcine contralateral extension, (b) T-2 weighted image (axial section) producing homogenous hyperintense signals, (c) gadolinium-enhanced T-1 weighted image (sagittal section) showing no uptake of contrast material. The lesion is seen to be producing a mass effect without any surrounding edema. These findings are suggestive of an epidermoid cyst.

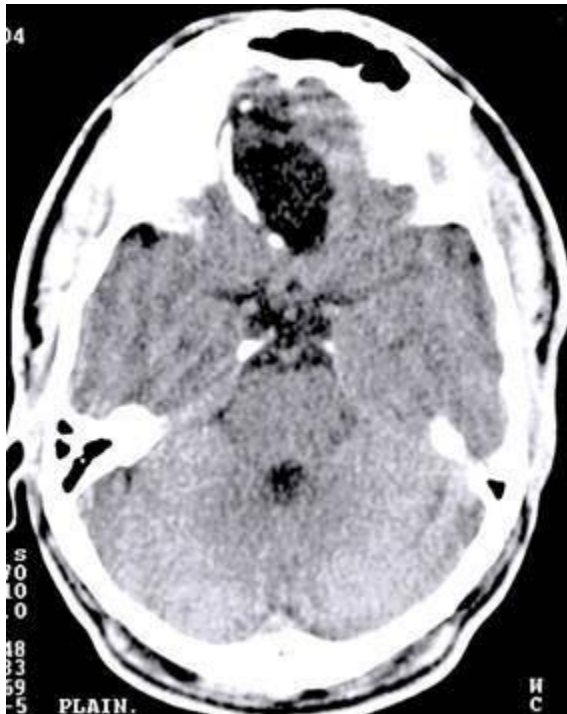

Figure 2: Unenhanced CT scan brain (axial section) of patient 2, showing a hypodense mass lesion in the fronto-basal location, mainly on the right side. Right lateral wall of cyst is lined with calcifications.

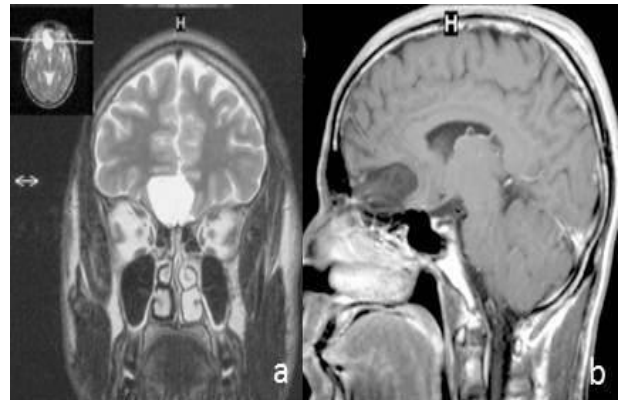


Figure 3: MRI brain of patient 2, (a) T-2 weighted MRI (coronal section) revealing a midline fronto-basal mass producing homogenous hyperintense signals without any perifocal edema, (b) post-gadolinium T-1 weighted MRI (sagittal section) showing no post-contrast enhancement. The features suggest the diagnosis of a fronto-basal epidermoid cyst.

REFERENCES

1. Bailey P. Cruveilhiers tumeur perlees. *Surg Gynecol obstet.* 1920;31:390-401.
2. Cushing H. A large epidermal cholesteatoma of the parieto-temporal region deforming the left hemisphere without cerebral symptoms. *Surg Gynecol obstet.* 1922;34:557-66.
3. Berger MS, Wilson CB. Epidermoid cysts of the posterior fossa. *J Neurosurg.* 1985;62:214-9.
4. Hsieh CH, Huang KM, Kao MC, Peng S, Wang CC. Hemorrhage in intracranial epidermoid cyst. *J Formos Med Assoc.* 1996;95:173-5.
5. Yamakawa K, Shitara N, Genka S, Manaka S, Takakura K. Clinical course and surgical prognosis of 33 cases of intracranial epidermoid tumors. *Neurosurgery.* 1989;24:568-73.
6. Barnett FC, Barnett JC, Jr. Massive bifrontal epidermoid tumor. *Surg Neurol.* 1992;38:437-40.
7. Russell DS, Rubinstein LF. Dermoid and epidermoid cysts. In: E A, editor. *Pathology of Tumors of the Nervous System.* London 1989. p. 690-5.
8. Ahmed I, Auguste KI, Vachhrajani S, Dirks PB, Drake JM, Rutka JT. Neurosurgical management of intracranial epidermoid tumors in children. Clinical article. *J Neurosurg Pediatr.* 2009;4:91-6.
9. Gao PY, Osborn AG, Smirniotopoulos JG, Harris CP. Radiologic-pathologic correlation. Epidermoid tumor of the cerebellopontine angle. *AJNR Am J Neuroradiol.* 1992;13:863-72.
10. Ulrich J. Intracranial Epidermoids. A Study on Their Distribution and Spread. *J Neurosurg.* 1964;21:1051-8.
11. Short JG, Marx WF. *Brain Epidermoid Imaging.* 2009; Available from: <http://emedicine.medscape.com/article/340467-overview>
12. Iaconetta G, Carvalho GA, Vorkapic P, Samii M. Intracerebral epidermoid tumor: a case report and review of the literature. *Surg Neurol.* 2001;55:218-22.
13. Cecchini A, Pezzotta S, Paoletti P, Rognone F. Dense dermoids in craniocervical region. *J Comput Assist Tomogr.* 1983;7:479-83.

14. Li F, Zhu S, Liu Y, Chen G, Chi L, Qu F. Hyperdense intracranial epidermoid cysts: a study of 15 cases. *Acta Neurochir (Wien)*. 2007;149:31-9; discussion 9.
15. Talacchi A, Sala F, Alessandrini F, Turazzi S, Bricolo A. Assessment and surgical management of posterior fossa epidermoid tumors: report of 28 cases. *Neurosurgery*. 1998;42:242-51; discussion 51-2.
16. Hao S, Tang J, Wu Z, Zhang L, Zhang J, Wang Z. Natural malignant transformation of an intracranial epidermoid cyst. *J Formos Med Assoc*. 2010;109:390-6.
17. Ge P, Luo Y, Fu S, Ling F. Recurrent epidermoid cyst with malignant transformation into squamous cell carcinoma. *Neurol Med Chir (Tokyo)*. 2009;49:442-4.
18. Anton-Badiola I, San Miguel-Fraile P, Peteiro-Cancelo A, Ortiz-Rey JA. [Squamous cell carcinoma arising on an epidermal inclusion cyst: a case presentation and review of the literature]. *Actas Dermosifiliogr*. 2010;101:349-53.
19. Kano T, Ikota H, Kobayashi S, Iwasa S, Kurosaki S, Wada H. Malignant transformation of an intracranial large epidermoid cyst with leptomeningeal carcinomatosis: case report. *Neurol Med Chir (Tokyo)*. 2010;50:349-53.
20. Nakao Y, Nonaka S, Yamamoto T, Oyama K, Esaki T, Tange Y, et al. Malignant transformation 20 years after partial removal of intracranial epidermoid cyst--case report. *Neurol Med Chir (Tokyo)*. 2010;50:236-9.
21. Hamlat A, Hua ZF, Saikali S, Laurent JF, Gedouin D, Ben-Hassel M, et al. Malignant transformation of intra-cranial epithelial cysts: systematic article review. *J Neurooncol*. 2005;74:187-94.
22. Roy K, Bhattacharyya AK, Tripathy P, Bhattacharyya MK, Das B. Intracranial epidermoid--a 10-year study. *J Indian Med Assoc*. 2008;106:450-3.