

Limb Salvage after Infrapopliteal Angioplasty for Critical Limb Ischemia in Surgically High-Risk Patients in Iran

Mohammad Ali Ostovan¹, Maryam Tavassoli¹, Afshin Ghofraniha², Mirmohammad Hosseinali Sharifian Davaei³, Javad Kojuri¹

¹ Department of Medicine, Division of Cardiology, Nemazee Hospital, Shiraz University of Medical Science, Shiraz, Iran

² Department of Medicine, Division of Cardiology, Kasra Hospital, Tehran University of Medical Science, Tehran, Iran

³ Department of Medicine, Division of Cardiology, Kordkui Heart Hospital, Gorgan University of Medical Science, Gorgan, Iran

ABSTRACT

INTRODUCTION: Surgical bypass for the treatment of lower extremity peripheral arterial disease is a suboptimal option in high-risk surgical patients or patients with limited life expectancy. Percutaneous transluminal angioplasty (PTA) is an alternative in such patients; however, the results of this approach have not been well-studied in our region. This study evaluated the results of infrapopliteal percutaneous transluminal angioplasty and/or stenting for critical limb ischemia (CLI) due to peripheral arterial disease of lower limbs in surgically high-risk patients.

METHODS: We conducted a retrospective study in four medical centers in Iran, from May 2006 to September 2009. Patients with CLI (Rutherford category 4-6), multiple two-vessel lesions, ankle-brachial index (ABI) of less than 0.05, high surgical risk category, and a follow-up of > 1 year after percutaneous transluminal angioplasty were included. Patients with restenosis of graft lesions, a life expectancy of less than 1 year, or those who were thienopyridine intolerant were excluded. "Limb salvage" was defined as a reduction in stenosis or occlusion to less than 30%. The primary endpoint was limb salvage rate. Survival and patency were evaluated with the

Kaplan-Meier method.

RESULTS: Sixty patients met the inclusion criteria. Mean age was 60.5±8.4 years (men 73.3%, diabetes mellitus 83.3%, current smoker 33.3%, hypertension 70%) and baseline ABI was 0.51±0.08. Anterior tibial artery (47%) was the most frequently involved blood vessel. A total of 22 stents and 122 balloon angioplasties were used in 98 limbs. "Limb salvage" was achieved in 58 (96.6%) patients immediately after the procedure. One-year salvage rate was 88.3%. Complete ulcer healing was achieved in 64.3% patients, and partial healing was obtained in 26.4%. Only one major procedure-related complication was reported; perforation with post-operative compartment syndrome. Major arterial access site complications (n=3, 5%) included two hematomas and a pseudoaneurysm. One-year survival rate was 96.6%. One-year major amputation rate was 11.7%.

CONCLUSIONS: Infrapopliteal angioplasty alone or with stenting is a valuable treatment option for the prevention of amputations in patients with CLI for whom surgical bypass is not an option and in whom the risk of amputation is high.

Key words: Critical limb ischemia; below-the-knee; percutaneous transluminal angioplasty; Peripheral Arterial Disease.

Conflicting Interest:
None declared

This article has been peer reviewed.

Article Submitted on:
24th April 2011

Article Accepted on:
28th August 2011

Funding sources: None declared

Correspondence to:
Javad Kojuri

Address:
Division of Cardiology,
Nemazee Hospital,
Shiraz University of
Medical Science,
Shiraz, Iran

Email:
kojurij@yahoo.com

INTRODUCTION

Atherosclerosis is a common cause of morbidity and mortality with a prevalence of 11.4% to 33.8% in individuals above 60 years of

Age [1, 2] The prevalence of intermittent claudication, a symptom of peripheral arterial atherosclerosis, is estimated to be present in 6-10% of the elderly population.

Of these, 10–20% may develop severe limb-threatening ischemia, requiring endovascular or surgical revascularization and in some cases, even amputation [3]. Despite the high burden of morbidity, few studies have focused on peripheral arterial disease (PAD) in contrast to coronary artery disease, and additional studies are needed.

Critical limb ischemia (CLI) is a manifestation of an advanced stage of PAD, characterized by pain at rest, ulcerations or gangrene of the limb, and association with evidence of reduced blood flow [4]. CLI mostly involves infrapopliteal arteries. Revascularization is necessary to save the limb and can be performed surgically or percutaneously [5]. When both are possible, percutaneous transluminal angioplasty (PTA) is preferred to surgery due to similar outcomes but lower morbidity and cost [6]. A particular challenge in performing infrapopliteal PTA is the small size of the tibial artery and its tendency to spasm [7, 8]. While bypass surgery of the lower extremity is the treatment of choice for limb salvage in CLI, surgical bypass may not be a good option for patients with limited life expectancy, poor distal target vessels, lack of an adequate autologous venous conduit, or significant comorbid conditions. For such poor surgical candidates, options are limited to PTA or amputation, the latter associated with higher mortality and morbidity [9, 10]. Infrapopliteal arteries are commonly involved. Thus, PTA of infrapopliteal arteries is a viable alternative in situations when the success of surgical and percutaneous approach are equally likely or when patient characteristics prohibit the use of surgical approach. While considerable data is available on the long-term results of infrapopliteal PTA from other countries, such data from Iran is lacking. Therefore, our aim in this study was to evaluate the long-term results of infrapopliteal PTA and/or stenting for limb salvage in Iran.

METHODS

We conducted a retrospective study, in four metropolitan centers in Iran: Shiraz, Tehran, Gorgan and Esfahan, from May 2006 to September 2009. Patients with CLI who were poor candidates for surgery and had been followed for 1 year after the procedure were included in the study. In our study, CLI was defined as: (1) Rutherford category 4-6⁴, (2) multiple two-vessel lesions (including the tibioperoneal trunk, or both of the anterior and posterior tibial arteries and a segment of the peroneal artery) assessed by angiography, and (3) the ankle-brachial index (ABI) of less than 0.05. Patients with restenosis of graft lesions or with a life expectancy of less than 1 year were excluded, as were those who were thienopyridine intolerant. Follow-up examinations were done up to 1 year post-intervention and included clinical

examination, evaluation for limb salvage and patency rates with Doppler and angiography. “Limb salvage” in our study was defined as a reduction in arterial stenosis or occlusion to less than 30% measured at the narrowest point of vascular lumen by angiogram. “Clinical success” was defined as the disappearance of pain at rest, healing of an ulcer and avoidance of “major” amputation. Major amputation was removal of part of lower limb either above or below the level of the knee. The primary endpoint was limb salvage rate; other endpoints were partial or complete ulcer healing. Data was entered and analyzed on SPSS version 15. Mean \pm standard deviation (SD), or if the distribution was non-Gaussian, median with range was calculated for quantitative variables. Survival and patency was evaluated with the Kaplan-Meier method.

PROCEDURE

All 4 centers had similar procedure protocols for PTA. Before angioplasty, all the patients received clopidogrel (75 mg daily) for eight days. After establishing arterial access, they received intravenous unfractionated heparin (70u/kg) according to a standard protocol¹¹. Femoral antegrade access was preferably used if possible; otherwise crossover technique was performed. 5F or 6F sheaths were used.

PTA was done with Amphirion deep balloons (Invatec) with 6-10 atm pressure and a diameter of 20-40 mm, and if needed, a stent was implanted (Chromis deep or rarely other bare stents). Stent deployment was used not only for post-ballooning arterial dissection, but also for selected cases with complex ulcer, flow-limiting dissection or residual stenosis of more than 30%. Distal runoff was evaluated by angiography during the procedure and then the sheaths were sutured percutaneously. All patients were discharged on clopidogrel (75 mg daily) for 2 months or longer.

RESULTS

Our retrospective medical record review identified 60 patients (73.3% men, mean age 60.5 \pm 8.6 years) in whom PTA was performed at four centers in Iran between May 2006 and September 2009 (Table 1). All patients had a non-healing or gangrenous ulcer (Rutherford grade 5 to 6), were poor candidates for surgery (vascular surgeons had declined to attempt surgical repair in all the cases), and had been followed clinically for at least for 1 year after the PTA. The study included 98 consecutive infrapopliteal angioplasties. Baseline ABI was 0.51 \pm 0.08. The most frequent comorbid conditions were non-insulin-dependent diabetes mellitus (83.35%, n=50) and hypertension (70%, n=42). Anterior tibial artery was the most frequent site of stenosis (47%) (Table 2). A total of 124 PTA procedures (2 stents only, 20 balloon angioplasty with stenting, and 102 balloon angioplasties alone)

were done for 98 limbs. Stenosis or occlusion was reduced to less than 30% (that is the limb salvage rate) in 58 (96.6%) patients (Tables 1 and 2).

Variable	n (%)
Age in years (mean with range)	60.5±8.6 (48.8-80.4)
Gender (male)	44 (73.3)
Prior history of coronary artery bypass graft	4 (6.6)
Hypertension	42 (70)
Hypercholesterolemia	16 (26.6)
Active smoker	20 (33.3)
Type II diabetes mellitus	50 (83.3)
Type I diabetes mellitus	6 (10)

Table 1: Patients' demographics and clinical characteristics (n=60)

Total number of limbs treated	98
Total number of stents deployed	22
Total number of arteries treated	124
Popliteal artery	4 (3.2%)
Tibio-peroneal trunk artery	26 (20%)
Anterior tibial artery	46 (37%)
Peroneal artery	14 (11.2%)
Posterior tibial artery	34 (27%)
Ankle brachial index	0.51±0.08

Table 2: Procedural and vessel characteristics (n=98)

The anterior tibial artery was perforated in one patient during operation leading to compartment syndrome in the early postoperative period. Major arterial access site complications included two cases with an extensive early post-operative hematoma not requiring blood transfusion, and one patient with early post-operative access-site pseudoaneurysm. There were no other major complications.

One-year salvage rate was 88.3% (n=53). Complete ulcer healing was seen in 64.3% patients and partial healing was seen in 26.4% (Table 3). A cardiovascular event led to the death of a patient. One-year survival rate was 96.6%, thus the estimated mean time of cumulative survival was 11.4±0.29 months (10.83 to 11.96 months). Leg major amputation rate was 11.7% (7 cases: 2 cases after 3 months, one case after 4 months, one after 6 months, one after 8 months and two after 12 months).

DISCUSSION

We have found that the overall success rate of PTA is quite high at one-year follow-up. We found one-year salvage rate of 88.3%, an ulcer healing rate of 90.6% (64.3% complete healing, 26.4% partial healing), and a major procedural

Limb salvage rate (procedural success)	96.6%
Cumulative one-year limb salvage rate	53 (88.3%)
Complete ulcer healing	38.3 (64.3%)
Partial ulcer healing	15.8 (26.4%)
One-year survival	58 (96.6%)
Major complications	1 (1.6%)*
Arterial access site complications	3 (5%)**
Major amputation	7 (11.7%)

Table 3: Patient follow-up and clinical outcome
*One perforation with compartment syndrome
**Two major hematomas not requiring transfusion, one pseudoaneurysm

complication rate of 1.6%. Stents were used in 22 (23.3%) of the 124 arteries which were treated. Major amputation rate was 11.7%.

The limb salvage rate in our study was higher than the 73% rate of successful limb salvage and ulcer healing reported by Keeling and colleagues in elderly Irish patients [12]. On the other hand, the one-year limb salvage rate (88.3%) compares favorably with the rate obtained from other studies using pure balloon angioplasty (13-80%) [13]. In most previous studies, only balloon angioplasty was used for PTA of infrapopliteal arteries, and stent angioplasty was limited to cases with dissection after balloon angioplasty. Our use of stents was somewhat more liberal as we also used PTA with stents for selected cases with complex ulcer, flow limiting dissection or residual stenosis of more than 30%.

To examine the effect of PTA on ulcer healing, Feiring et al evaluated 82 patients with either CLI or severe claudication due to infrapopliteal lesions. They achieved a 96% ulcer healing rate and their technical success rate was 94% [14]. Stenting in this vessel bed appeared to be technically more successful than PTA, and also had higher patency rates [15]. Scheinert et al, based on follow-up data of 112 patients treated with either PTA alone or PTA with stenting in the infrapopliteal vessels, showed that one-year patency rate was significantly higher (83%) in the PTA with stent group [16]. Rand et al determined the primary success rate and short-term patency rates of PTA versus stent PTA using carbofilm coated stents in 95 BTK lesions. Primary success rates were equal but primary patency rate in the stent group was significantly better at 6 months follow-up [17]. A limitation of the study was the lack of availability of documentation of risk factors that may have affected the patency and survival rate in patients.

Although previous research showed that bypass is a preferable option than PTA in CLI because it improves overall survival and amputation-free survival [18], we found that PTA of the infrapopliteal artery in poor surgical candidate CLI patients had good limb salvage (96.6%) result and fewer "major" complications. In patients with

CLI, PTA for infrapopliteal arteries should be considered among other alternative therapies. We suggest that surgically poor candidates who are at high risk for amputation due to CLI should be evaluated by a vascular specialist with experience in lower limb PTA for possible limb salvage via endovascular approach.

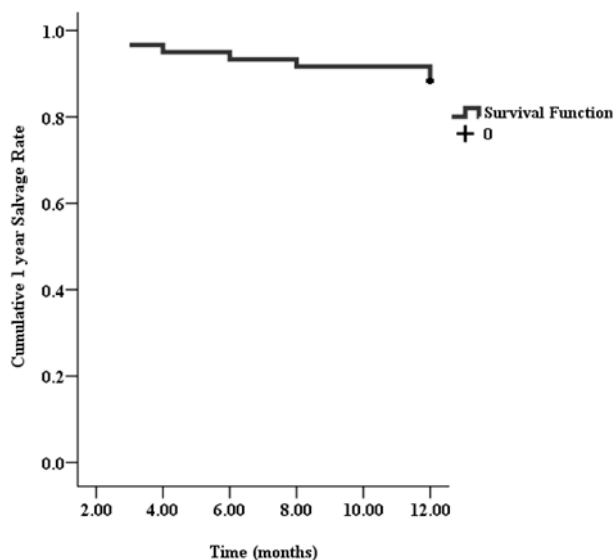


Figure 1: Cumulative one-year limb salvage rate (Kaplan-Meier method) (n=98). Primary patency rate at 1 year was 88.3%.

COMPETING INTERESTS

The authors declare that they have no competing interests.

ACKNOWLEDGMENTS

We appreciate Seied Reza Ghaemi and Masih Tavassoli's help in data analysis. We also thank the Center for Development of Clinical Research of Nemazee Hospital and K. Shashok (Author AID in the Eastern Mediterranean) for help in preparation of this manuscript.

REFERENCES

- Schroll M, Munck O. Estimation of peripheral atherosclerotic disease by ankle blood pressure measurements in a population of 60 year old men and women. *J Chron Dis* 1981;34:261-269.
- Criqui MH, Langer RD, Fronek A, Feigelson HS, Klauber MR, McCann TJ, et al. Mortality over a period of 10 years in patients with peripheral arterial disease. *N Engl J Med* 1992;326:381-386.
- Criqui MH, Denenberg JO, Langer RD, Fronek A. The epidemiology of peripheral arterial disease: importance of identifying the population at risk. *Vasc Med* 1997;2:221-226.
- Rutherford RB, Baker D, Ernst C, Johnston KW, Porter JM, Ahn S, et al. Recommended standards for reports dealing with lower extremity ischemia: revised version. *J Vasc Surg* 1997;26:517-538.
- Norgren L, Hiatt WR, Dormandy JA, Nehler MR, Harris KA, Fowkes FG. TASC II Working Group. Inter-society consensus for the management of peripheral arterial disease (TASC II). *Eur J Vasc Endovasc Surg* 2007;33(suppl 1):S1-75.
- Adam DJ, Beard JD, Cleveland T, Bell J, Bradbury AW, Forbes JF, et al. Bypass versus angioplasty in severe ischaemia of the leg (BASIL): multicentre randomized controlled trial. *Lancet* 2005;366:1925-1934.
- Bertelè V, Roncaglioni MC, Pangrazzi J, Terzian E, Tognoni EG. Clinical outcome and its predictors in 1560 patients with critical leg ischaemia. Chronic Critical Leg Ischaemia Group. *Eur J Vasc Endovasc Surg* 1999;18:401-410.
- Marston WA, Davies SW, Armstrong B, Farber MA, Mendes RC, Fulton JJ, et al. Natural history of limbs with arterial insufficiency and chronic ulceration treated without revascularization. *J Vasc Surg* 2006;44:108-114.
- Gray BH, Sullivan TM, Childs MB, Young JR, Olin JW. High incidence of restenosis/re-occlusion of stents in the percutaneous treatment of long-segment superficial femoral artery disease after suboptimal angioplasty. *J Vasc Sur* 1997;25:74-83.
- Keagy BA, Schwartz JA, Kotb M, Burnham SJ, Johnson G Jr. Lower extremity amputation: the control series. *J Vasc Surg* 1986;4:321-326.
- Hirsh J, Warkentin TE, Raschke R, Granger C, Ohman EM, Dalen JE. Heparin and low molecular weight heparin. *Chest* 1998;114(Suppl):489-510.
- Keeling AN, Khalidi K, Leong S, Wang TT, Ayyoub AS, McGrath FP, et al. Below knee angioplasty in elderly patients: Predictors of major adverse clinical outcomes. *Eur J Radiol* 2011;77:483-489.
- Brillu C, Picquet J, Villapadierna F, Papon X, L'HosteP, Jousset Y, et al. Percutaneous transluminal angioplasty for management of critical ischemia in arteries below the knee. *Ann Vasc Surg* 2001;15:175-181.
- Feiring AJ, Weolowski AA, Lade S. Primary stent-supported angioplasty for treatment of below-knee critical limb ischemia and severe claudication: Early and one-year outcomes. *J Am Coll Cardiol* 2004;44:2307-2314.
- Balzer JO, Khan V, Thalhammer A, Vogl TJ, Lehnert T. Below the knee PTA in critical limb ischemia results after 12 months: Single center experience. *Eur J Radiol* 2010;75:37-42.
- Scheinert D, Biamino G. Recanalization techniques in popliteal and tibial occlusive disease: In proceeding of *Euro PCR* May 2004;452-9.
- Rand T, Basile A, Cejna M, Fleischmann D, Funovics M, Gschwendtner M, et al. PTA versus carbofilm-coated stents in infrapopliteal arteries: pilot study. *Cardiovasc Intervent Radiol* 2006;29:29-38.
- Dotter CT, Judkins MP. Transluminal treatment of atherosclerotic obstruction. Description of a new technique and a preliminary report of its application. *Circulation* 1964;30:654-670.