

Pneumothorax as a Result of Acupuncture

Nathan C. Claydon, MD¹

¹Sierra Nevada Memorial Hospital, Grass Valley, California, USA

A 35-year-old female with chronic pain believed to arise from a nodule on the right shoulder presented to an acupuncturist on the day of admission seeking relief from this pain. Two acupuncture needles were introduced into the areas marked with "X" on the patient in Figure 1

with resulting severe pleuritic pain once the needles were retracted. The patient continued to have severe pain and presented herself to the Emergency Department for further evaluation. A Chest X ray revealed an apical pneumothorax as shown in Figure 2 and Figure 3.

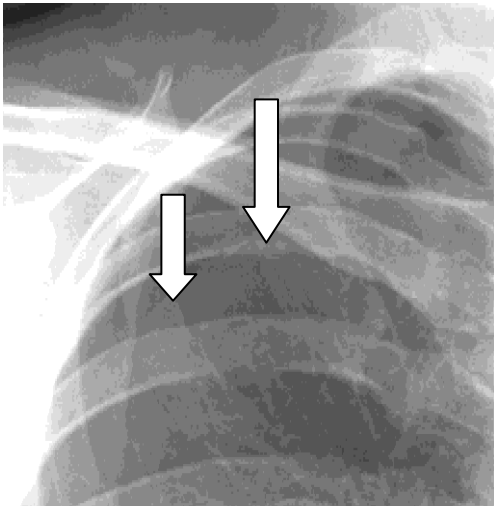
Figure 1: Acupunctures on areas marked X

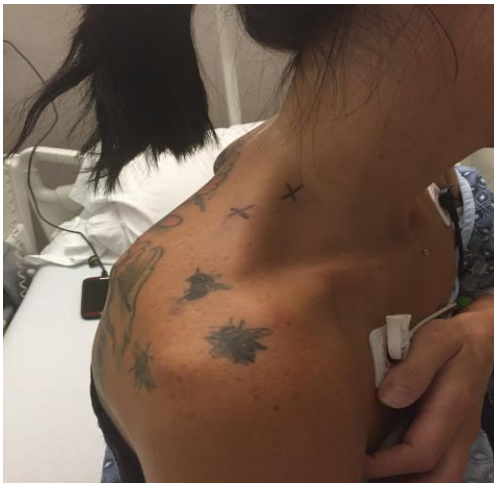

Figure 2: Apical pneumothorax on X ray

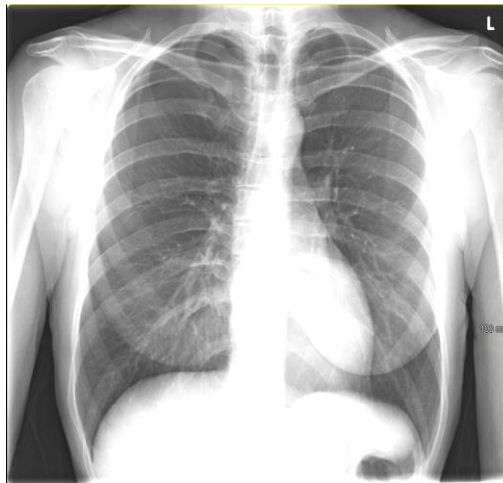

Figure 3: Apical pneumothorax on X ray



Conflict of Interest: None declared

This article has been peer reviewed.

Article Submitted on: 29th August 2017

Article Accepted on: 15th September 2017

Funding Sources: None declared

Correspondence to: Dr Nathan C. Claydon

Address: Sierra Nevada Memorial Hospital, Grass Valley, California, USA

Email: nathanclaydon@gmail.com

Cite this article: Claydon NC. Pneumothorax as a result of acupuncture. *J Pioneer Med Sci.* 2017; 7(4):48