

# Returning a Child's Smile: Adhesive Reattachment of a Tooth Fragment

Paras Angrish<sup>1</sup>, Kashika Arora<sup>1</sup>, Anuj Kumar Pathak<sup>1</sup>, Nitin Khanduri<sup>2</sup>, Manu Batra<sup>3</sup>

<sup>1</sup>Post graduate student, Department of Pedodontics and Preventive Dentistry, Dr. R Ahmed Dental College and Hospital Sealdah, West Bengal, India

<sup>2</sup>Senior Lecturer, Department of Pedodontics and Preventive Dentistry, Institute of Dental Education and Advanced Gwalior, Madhya Pradesh, India

<sup>3</sup>Senior Lecturer, Department of Public Health Dentistry, Surendera Dental College and Research Institute, Sri Ganganagar, Rajasthan, India

## ABSTRACT

Recent developments in restorative materials, placement techniques, preparation design, and adhesive protocols allow clinicians to predictably restore fractured teeth. Using a minimally invasive approach, treatment of the maxillary anterior region can be effortlessly completed within a single appointment. If the original tooth fragment is retained following fracture, the natural tooth

structures can be reattached using adhesive protocols to ensure reliable strength, durability, and aesthetics. This article discusses the adhesive reattachment of a tooth fragment to a fractured incisor using a conservative preparation technique. It also restores function, provides a positive psychological response, and is a relatively simple procedure.

Keywords: Fragment Reattachment; Tooth Fracture; Smile

## INTRODUCTION

Coronal fractures of the anterior teeth are a common form of dental trauma that mainly affects children and adolescents [1,2]. Approximately, one out of every four persons under the age of 18 sustain a traumatic anterior crown fracture [3,4]. Studies reveal that the most common injury to tooth is an uncomplicated crown fracture (fracture of the enamel and dentin without pulpal exposure). Majority of the fractures involved the maxillary central incisors, with boys outnumbering girls almost two to one [3,5,6]. During the last century, clinicians utilized a variety of procedures (e.g. pin-retained resin, orthodontic bands, modified three-quarter crowns, full-coverage gold with bonded porcelain, porcelain jacket crowns, porcelain bonded crowns, porcelain inlays) for the restoration of the fractured crown [7]. These earlier restorative procedures provided function only. Adolescents, maybe more so than adults, are prone to social and psychological implications as a result of the appearance from metal in the mouth, which can compromise aesthetics [8]. Recent developments in restorative materials, placement techniques, preparation design, and adhesive protocols facilitate

restoration of fractured maxillary incisors. Early restorative materials (eg, silicates, acrylics) have been replaced by hybrid, microfill, and microhybrid composites. Traditional hybrid and microfill composites required the use of feather-edge, chamfer, shoulder, or long bevel preparation designs to facilitate the strength, sculptability, polishability, and durability provided by these materials. The feather-edge preparation required an overlay of composite resin that increased the volume of the composite on the labial and lingual enamel, which resulted in incisal breakdown, staining, and loss of retention [9]. The chamfer, shoulder, and long bevel preparation design provided a finish line and an increased volume of restorative material at the restorative margin, while maintaining the original contours of the tooth [10].

The concept of reattachment began in 1964 when Chosak and Idleman used a cast post and conventional cement to attach an anterior crown segment on a 12 year old boy [11]. Anterior tooth fragments have since been reattached using composite, interlocking mini-pins, and light cure resins [12]. In the following years, various techniques have been described for reattachment of original tooth fragment using acid etch bonding various tooth preparation techniques,

Conflict of Interest: None declared

This article has been peer reviewed.

Article Submitted on: 1<sup>st</sup> January 2015

Article Accepted on:

Funding Sources: None declared

Correspondence to: Dr Paras Angrish

Address: Department of Pedodontics and Preventive Dentistry, Dr. R Ahmed Dental College and Hospital Sealdah, West Bengal, India

E-mail: [drparasanqrish@gmail.com](mailto:drparasanqrish@gmail.com)

Cite this Article: Angrish P, Arora K, Khanduri N, Pathak AK, Batra M. Returning child's smile-adhesive reattachment of a tooth fragment. *J Pioneer Med Sci* 2016; 6(1):27-32

and a light and chemically cured composite resin [13]. No significant difference has been noted. However, in the fracture resistance of tooth prepared with a 45 degree external circumferential bevel, with no mechanical preparation for creation of "biological restoration" [14,15].

Tooth fragment reattachment offers a conservative, esthetic, and cost effective restorative option that has been shown to be an acceptable alternative to the restoration of the fractured tooth with resin-based composite or full-coverage crown [16, 17,18]. Reattachment of a fragment to the fractured tooth can provide good and long-lasting esthetics (because the tooth's original anatomic form, color, and surface texture are maintained), [19] can restore function, can result in a positive psychological response, and is a reasonably simple procedure [20]. In addition, tooth fragment reattachment allows restoration of the tooth with minimal sacrifice of the remaining tooth structure. Furthermore, this technique is less time-consuming and provides a more predictable long-term wear than when direct composite is used [21]. Clinical trials and long-term follow-up have reported that reattachment using modern dentin bonding agents or adhesive luting systems may achieve functional and esthetic success [16, 22].

Several aspects may govern the choice of a reattachment technique. Studies have reported that the primary cause of fragment loss is new dental trauma or the non physiological use of the restored tooth [6]. Therefore, most concerns about reattachment techniques have been directed toward the fracture strength of the restored tooth [23].

Clinicians have employed an assortment of bevel designs, chamfers, dentinal and enamel grooves, and choices of resin composite materials and techniques for the reattachment of tooth fragments. Reis and colleagues [5] have shown that a simple reattachment with no further preparation of the fragment or tooth was able to restore only 37.1% of the intact tooth's fracture resistance, whereas a buccal chamfer recovered 60.6% of that fracture resistance; bonding with an over contour and placement of an internal groove nearly restored the intact tooth fracture strength, recovering 97.2 and 90.5% of it, respectively.

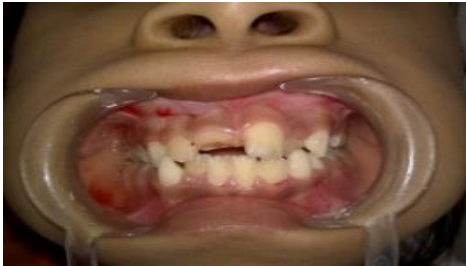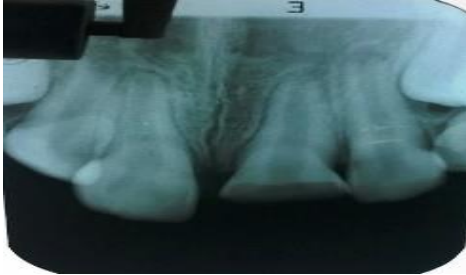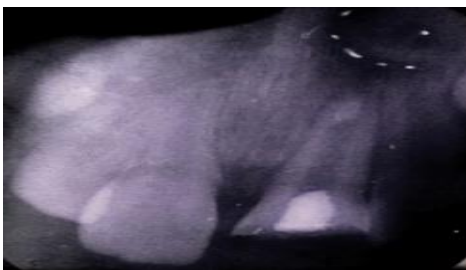
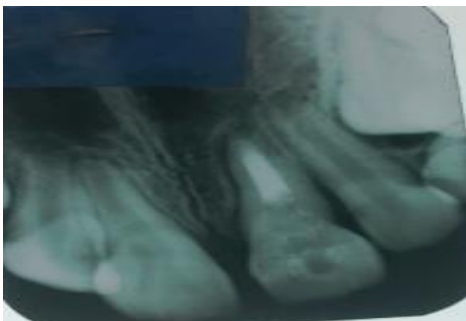In cases of complicated fractures, when endodontic therapy is required, the space provided by the pulp chamber can be used as an inner reinforcement, thus avoiding further preparation of the fractured tooth [24, 25].

However, in such cases, esthetics may become an important issue as pulpless teeth lose part of their translucency and brightness. This article reports on two coronal tooth fracture cases that were successfully treated using tooth fragment reattachment.

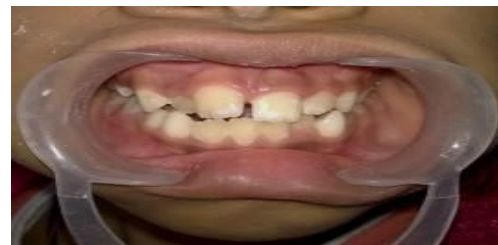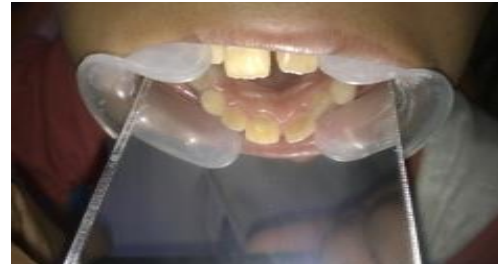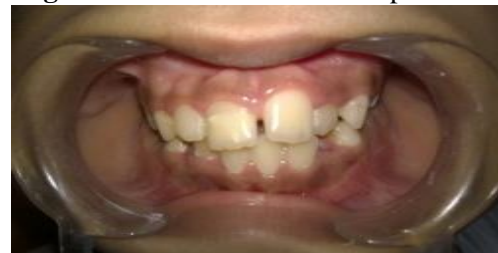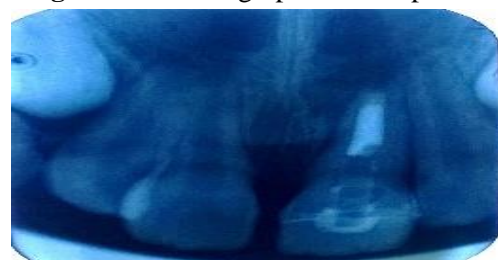## CASE REPORT

### Case: 1

A 9 year old girl reported to the Department of Pedodontics and Preventive Dentistry with the chief complaint of trauma in upper front tooth region due to fall from bed 1 week prior to presentation. The extra-oral examination revealed no significant findings. The clinical and radiographic maxillofacial examination indicated that the maxilla, mandible and other facial bones were intact. Intraorally, the maxillary left central incisor revealed complicated oblique crown fracture. The fracture line was oblique extending in apical direction from buccal to palatal surface. The margin on palatal surface was located about 2 mm from the free gingival margin and can be probed easily with a periodontal probe. In the periapical radiograph, apex was found to be open (Figure 2A). The crown fragment was brought by the patient. The apical fragment had no pathologic mobility. Other adjacent teeth had no sign of trauma and were vital. A detailed explanation about the treatment plan was given to the parent and patient and consent was taken. Local anesthesia was administered, and the fractured coronal fragment was immediately soaked in saline solution to prevent further dehydration (Figure 3A) . A decision was made to do MTA apexification followed by placement of a fiber-reinforced polymer post (Ribbond, Ribbond Inc. Seattle Washington, USA) into the root canal for retention. Following extirpation of the pulp tissue, MTA was plugged in open apex 3.5 mm (Figure 4A) and sectional obturation with gutta-percha and resin sealer was done. sealer (Sealapex®, Kerr Corporation, Orange California, USA).The day after the root canal treatment, Before reattachment, the fractured margins were checked to ensure an accurate fit. A small hole was created in the middle of the crown fragment in which to lay the polyethylene fiber. Isolation with respect to crevicular fluid seepage was achieved with cotton rolls and gauzes. Dual cure resin was used to secure fiber post (Figure 5A). The tooth and fragment were etched for 15 seconds with phosphoric acid, rinsed for 5 seconds, gently dried for 5 seconds, and lightly air thinned to avoid desiccation.

**Figure 1A:** Fractured**Figure 2A:** Radiograph Pre Op**Figure 3A:** Fragmented Segment**Figure 4A:** MTA Apexification**Figure 5A:** Obturation, fiber post central incisor and reattached segments in radiograph

Bonding agent was applied to each and light cured for 20 seconds. A light-cured/dual-cured resin cement (eg, Nexus II, Kerr/Sybron, Orange, CA; VarioLink II, Ivoclar Vivadent, Ahmerst, NY; Illusion, Bisco, Schaumburg, IL) was injected onto the internal surface of the fragment (Figure 8). An adhesive applicator tip was used to seat the fragment firmly in place, and the excess resin cement was removed with a sable brush using the "Wet Brush Technique". It was imperative to leave some residual cement at the margins to prevent voids and to compensate for polymerization shrinkage. The biological restoration was polymerized from all aspects (ie, facial, incisal, lingual, proximal) for 60 seconds each. Once the resin cement was polymerized,

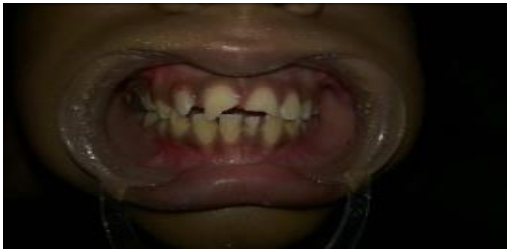**Figure 6A:** Reattached segment buccal view**Figure 7A:** Palatal view**Figure 8A:** 12 months follow up**Figure 9A:** Radiograph follow up

the residual excess at the restorative margin was finished with a series of finishing burs and then finished properly (Figure 6A,7A,8A). Follow up of 1 year was done and showed satisfactory results (Figure 8A,9A)

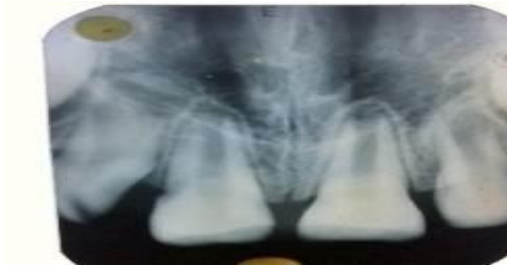#### Case 2:

A 8 year old male child reported to the Department of Pedodontics, with a broken crown fragment within 48 hours after trauma. Cause of trauma was fall injury, which lead to the fracture of both maxillary central incisors involving enamel, dentine in 11 (Ellis & Davey's class II) and very little pulp in 21 (Ellis & Davey's class III). On examination the fractured teeth were not mobile and there was no soft tissue injury (Figure 1B). Intra oral periapical radiograph and clinical examination showed pulp exposure in 21 whereas 11 showed little covering of dentine over it and incomplete root formation, there was no radicular or alveolar fracture (Figure 2B). The fractured fragment of left central 21 incisor was intact and was hydrated in normal saline (Figure 3B). The sharp edges of the crown and the fragment were

**Figure 1B:** Fractured Incisors



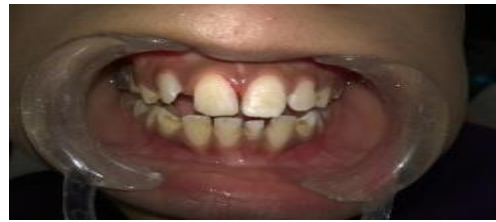**Figure 2B:** Pre-operative IOPA X-Ray



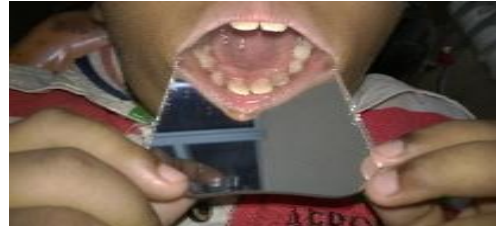**Figure 3B:** Fractured Segment



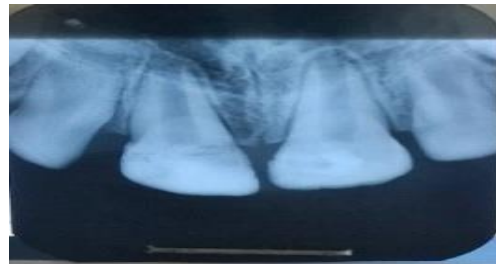**Figure 4B:** Reattached Segment



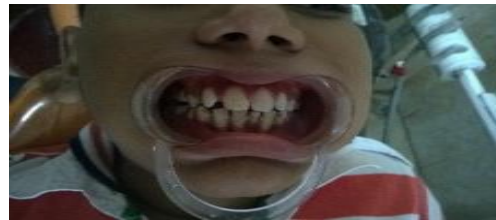**Figure 5B:** Palatal View



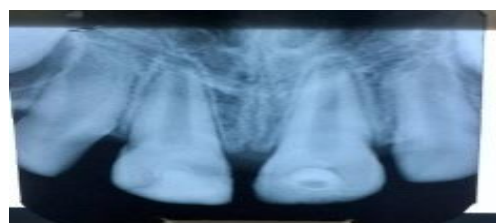**Figure 6B:** IOPA X-Ray after reattachment



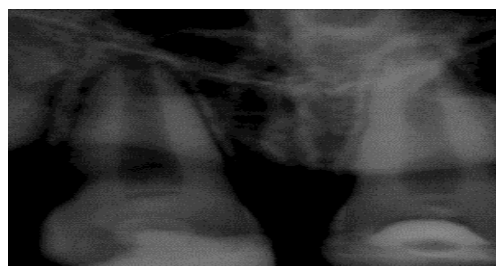
**Figure 7B:** 6 months follow up



**Figure 8B:** 3 months IOPA X-Ray



**Figure 9B:** 6 months IOPA X-Ray



rounded and bevel were given to increase the surface area on both incisors. In order to protect the pulp, calcium hydroxide (Dycal) was applied on the exposed dentin of right central incisor 11 followed by light cure composite build up and pulpotomy was decided for left central incisor 21, after achieving local anesthesia pulpotomy was performed in 21 and biodentine was used as a medicament. The fractured fragment was then united with the tooth using flowable light cure composite resin to reinforce the joint labially and palatally. Final polishing and finishing was done with rubber cups and polishing discs (Figure 4B, 5B). Initial follow up was done after 24 hours (Figure 6B) and recall visits were planned once in every 3 months thereafter (Figure 7B, 8B). As of now, 6 months post-operatively, there are no sign or symptom clinically and radiographically, which shows successful result. (Figure 9B).

## DISCUSSION

The techniques described in these case reports are reasonably simple, while restoring function and esthetics with a very conservative approach. Both cases were complicated crown fracture requiring endodontic therapies, the fractured fragments were available. In first case, reattachment of the fragments with fiber post is performed. Adhesive post is used as it has the potential for increased retention, is more flexible, and has modulus of elasticity approximately same as dentin, and when bonded with resin cement it distributes forces evenly along the root [26]. The most common complication of post and core system is debonding [27], another reason for failure is root fracture [28] Restoration with cast metal posts can cause wedging forces coronally that may result in irreversible failure because of fracture of an already weakened root [29] Whereas fiber reinforced composite resin post has demonstrated negligible root fracture. Studies have indicated that dentin-bonded resin post-core restorations provide significantly less resistance to failure than cemented custom cast posts and cores [30,31]. In addition, the fiber-reinforced posts are used with minimal preparation because it uses the undercuts and surface irregularities to increase the surface area for bonding, thus reducing the possibility of tooth fracture during function or traumatic injury [32]. Second case pulpotomy and conventional method of reattachment was used. However, the professional has to keep in mind that a dry and clean working field and the proper use of bonding protocol and materials is the key for

achieving success in adhesive dentistry. Reports and clinical Figure experience indicate that the reattachment of fractured coronal fragments results in successful short- and medium-term outcomes [14, 16, 17]. As with the conventional restoration, restorative success depends on proper case selection, strict adherence to sound principles of periodontal and endodontic therapies, and the techniques and materials for modern adhesive dentistry [33,34,35]

Fabrication of a mouth guard and patient education about treatment limitations may enhance clinical success as reattachment failures may occur with new trauma or parafunctional habits [10]. With the materials available today, in conjunction with an appropriate technique, esthetic results can be achieved with predictable outcomes. Thus, the reattachment of a tooth fragment is a viable technique that restores function and esthetics with a very conservative approach, and it should be considered when treating patients with coronal fractures of the anterior teeth, especially younger patients.

## REFERENCES

1. Dietschi D, Jacoby T, Dietschi JM, Schatz JP. Treatment of traumatic injuries in the front teeth: restorative aspects in crown fractures. *Pract Periodontics Aesthet Dent*. 2000;12(8):751-8.
2. Hamilton FA, Hill FJ, Holloway PJ. An investigation of dento-alveolar trauma and its treatment in an adolescent population. Part 1: the prevalence and incidence of injuries and the extent and adequacy of treatment received. *Br Dent J*. 1997;182:91-5.
3. Andreasen JO, Ravn JJ. Epidemiology of traumatic dental injuries to primary and permanent teeth in a Danish population sample. *Int J Oral Surg*. 1972;1(5):235-239.
4. Petti S, Tarsitani G. Traumatic injuries to anterior teeth in Italian schoolchildren: Prevalence and risk factors. *Endodont Dent Traumatol*. 1996;12(6):294-297.
5. Zerman N, Cavalleri G. Traumatic injuries to permanent incisors. *Endodont Dent Traumatol* 1993;9(2):61-64.
6. Badami AA, Dunne SM, Scheer B. An in vitro investigation into the shear bond strengths of two dentine-bonding agents used in the reattachment of incisal edge fragments. *Endodont Dent Traumatol*. 1995;11(3):129-135.
7. Andreasen JO, Andreasen FM. Dental trauma: Quo vadis? *Tandlaegebladet*. 1989;93(11):381-384.
8. Sheykholeslam Z, Oppenheim M, Houpt MI. Clinical comparison of sealant and bonding systems in the restoration of fractured anterior teeth. *J Am Dent Assoc* 1977;95(6):1140-1144. 10.
9. Bichacho N. Direct composite resin restorations of the anterior single tooth: Clinical implications and practical applications. *Compend Cont Educ Dent* 1996;17(8):796-802.
10. Rappelli G, Massaccesi C, Putignano A. Clinical procedures for the immediate reattachment of a tooth fragment. *Dent Traumatol* 2002;18(5):281-4.
11. Chosak A, Eidelman E. Rehabilitation of a fracture

- incisor using the patient's natural crown: case report. *J dental child* 1964;31:19-21
12. Spasser HF. Repair and restoration of a fractured, pulpally involved anterior tooth: Report of a case. *J Am Dent Assoc* 1977;94(3):519-520.
  13. Simonsen RJ. Restoration of a fractured central incisor using original tooth fragment. *J Am Dent Assoc* 1982;105(4):646-648.
  14. Diangelis AJ, Jungbluth M. Reattaching fractured tooth segments: Anesthetic alternative. *J Am Dent Assoc* 1992;123(8):58-63.
  15. Ddean JA, Avery DR, Swartz ML. Attachment of anterior tooth fragment. *Pediatr Dent* 1986;8(3):139-43
  16. Andreasen FM, Noren JG, Andreasen JO, et al. Long term survival of fragment bonding in the treatment of fractured crowns. *Quintessence Int* 1995;26:669-81.
  17. Baratieri LN, Ritter AV, Junior SM, Filho JCM. Tooth fragment reattachment: an alternative for restoration of fractured anterior teeth. *Pract Periodont Aesthet Dent* 1998;10: 115-27.
  18. El-Askary FS, Ghalab OH, Eldemerdash FH et al. Reattachment of a severely traumatized maxillary central incisor, one-year clinical evaluation: a case report. *J Adhes Dent* 2006;8(5):343-9.
  19. Reis A, Loguercio AD, Kraul A, Matson E. Reattachment of fractured teeth: a review of literature regarding techniques and materials. *Oper Dent* 2004;29(2):226-33.
  20. Baratieri LN, Monteiro S Jr., Andrada MAC. Tooth fracture reattachment: case reports. *Quintessence Int* 1990;21(4):261-70.
  21. Oz IA, Haytac MC, Toroglu MS. Multidisciplinary approach to the rehabilitation of a crown-root fracture with original fragment for immediate esthetics: a case report with 4-year follow-up. *Dent Traumatol* 2006;22(1):48-52.
  22. Farik B, Munksgaard EC, Andreasen JO. Impact strength of teeth restored by fragment-bonding. *Endod Dent Traumatol* 2000;16(4):151-3.
  23. Diangelis AJ, Jungbluth M. Reattaching fractured tooth segments: an esthetic alternative. *J Am Dent Assoc* 1992;123(8):58-63.
  24. Ehrmann EH. Restoration of a fractured incisor with exposed pulp using original tooth fragment: report of case. *J Am Dent Assoc* 1989;118(2):183-5.
  25. Andreasen FM, Steinhardt U, Bille M, Munksgaard EC. Bonding of enamel-dentin crown fragments after crown fracture. An experimental study using bonding agents. *Endodontics & Dental Traumatology*. 1993; 9 (3):111-114
  26. Lokesh P, Kala M. Management of mild-root fracture using MTA and fiber post to reinforce crown—a case report. *Indian Journal of Dental Research and Review*. 2008; 3:32-36
  27. Torbjörner A, Karlsson S, Dr O, Odman PA. Survival rate and failure characteristics for two post designs. *The Journal of Prosthetic Dentistry*. 1995; 73 (5): 439-444
  28. Asmussen E, Peutzfeldt A, Heitmann T. Stiffness, elastic limit, and strength of newer types of endodontic posts. *Journal of Dentistry*. 1999; 27 (4): 275-278
  29. Deutsch AS, Cavallari J, Musikant BL, Silverstein L, Lepley J, Petroni G. Root fracture and the design of prefabricated posts. *The Journal of Prosthetic Dentistry*. 1985; 53 (5): 637-640
  30. Beg RT, Parker MW, Judkins JT, Pelleu GB. Effect of dentinal bonded resin post-core preparations on resistance to vertical root fracture. *The Journal of Prosthetic Dentistry*. 1992; 67 ( 6):768-772
  31. Akkayan B, G'ulmez T. Resistance to fracture of endodontically treated teeth restored with different post systems. *The Journal of Prosthetic Dentistry*. 2002; 87(4): 431-437
  32. Trabert KC, Caputo AA, Abou-Rass M. Tooth fracture—a comparison of endodontic and restorative treatments. *Journal of Endodontics*. 1978; 4 (11): 341-345
  33. Andreasen FM, Steinhardt U, Bille M, Munksgaard EC. Bonding of enamel-dentin crown fragments after crown fracture. An experimental study using bonding agents. *Endodontics & Dental Traumatology*. 1993; 9 (3):111-114
  34. Cavalleri G, Zerman N. Traumatic crown fractures in permanent incisors with immature roots: a follow-up study. *Endodontics & Dental Traumatology* 1995; 11 (6): 294-296
  35. Lowey MN. Reattachment of a fractured central incisor tooth fragment. *British Dental Journal*. 1991; 70 (8): 285